

EKSPERIMENTINIAI TYRIMAI

Monitoring changes in heart tissue temperature and evaluation of graft function after coronary artery bypass grafting surgery

Raimundas Lekas, Povilas Jakuška, Algimantas Kriščiukaitis, Vincentas Veikutis, Gintautas Dzemyda¹, Tomas Mickevičius, Kristina Morkūnaitė², Alina Vilkė, Povilas Treigys¹, Genuvaitė Civinskienė³, Jonas Andriuškevičius³, Tomas Vanagas³, Kęstutis Skauminas, Jurga Bernatoniene³

Institute for Biomedical Research, Kaunas University of Medicine,

¹*Institute of Mathematics and Informatics, Vilnius,* ²*Institute of Cardiology, Kaunas University of Medicine,*

³*Kaunas University of Medicine, Lithuania*

Key words: *thermography; ischemia; autovenous graft; coronary artery bypass grafting.*

Summary. *Thermography is a relatively new contact-free method used in experimental and clinical studies and in cardiovascular surgery to investigate the myocardium and coronary artery function. Objects of complex study included mongrel dogs and patients with coronary artery disease who underwent cardiac surgery. For active dynamic thermography, we used a thermovision camera "A20V" (FLIR Systems, USA). Our data indicate that both experimental and clinical study performed on beating hearts could be an important approach to interoperation inspection of autovenous graft function. An infrared camera also can be successfully used to determine the extent of ischemic damage to the myocardium, heart, and blood vessels during surgery as a significant prognostic tool for evaluating outcome after cardiac operation.*

Introduction

Diagnostics of ischemic damage to the myocardium is an important problem in open-heart surgery, which can seriously influence the rate of postoperative complications and mortality. In many cases, the sudden death is caused by myocardial ischemia and is accompanied by fatal ventricular arrhythmias. It was proved that ischemia causes the slowdown of excitation spread, provokes formation of reentry arrhythmias, ventricular tachycardia, or ventricular fibrillation (VF). More often ventricular arrhythmia begins during the first 10–30 minutes after onset of acute ischemia. At the time of surgery, during the first 30 seconds of reperfusion, a marked inhomogeneity of the action potential fragmentation within the ischemic area and at the border zone is observed (1). Action potentials of different cells within the ischemic zone often are generated nonsynchronously, some showing relatively high amplitudes and long durations, while at the same time others show opposite changes. Action potential duration of cells close to the ischemic border may be shortened by as much as 60 to 100 ms during reperfusion (2, 3). During cardiac surgery including coro-

nary artery bypass grafting (CABG) operations with cardiopulmonary bypass (CPB) and cardioplegia, a surgeon requires further information regarding functional status of the heart to avoid acute cardiac events. Additional quantitative flow estimation likewise is desirable to detect graft failures as earlier as possible.

New technological achievements in thermographic imaging, such as advanced, uncooled micro bolometer FPA detector, deliver high-resolution long-wave infrared images that allow us to determine thermal variances as low as 0.12°C. Real-time image acquisition at standard video rates (up to 60 Hz) enables to see rapid, thermally transient events, which gives an opportunity to visualize surface temperature dynamics of the beating heart. Circulation disorders in the coronary arteries can be associated with local temperature changes in the cardiac tissue.

The main goals of the present study were to apply thermography as a method for visualization and evaluation of the heart anatomy and function, characteristics of coronary artery damage, and function (blood flow) of autovenous grafts during CABG surgery.

Methods

Thermography is a noninvasive method allowing assessment of changes of epicardial temperature in real time. At first, the emitted infrared radiation was recorded with a thermovision camera; therewith, recorded radiation after digital processing was presented in the form of a thermogram on the PC or TV screen. Our experiments were performed by using a thermovision camera "A20V" (FLIR Systems, USA).

Experiments were performed on mongrel dogs (n=8) of both sexes according to the permission of the Lithuanian Committee for Ethics of Good Laboratory Animal Use Practice (No. 0053/2005). All the animals were anesthetized with fentanyl (2 µg/kg), calypsol (50–70 mg/kg), relanium (10 mg/kg IM). Following anesthesia was maintained with fentanyl (2 µg/kg/h) and propofol (4–8 µg/kg/h) through IV cannula. The chest was opened via bilateral thoracotomy. Standard ECG leads (I, II, III), arterial blood pressure, and blood saturation with O₂ were registered throughout the study. Local ischemia was induced by temporal ligation of the left anterior descending (LAD) coronary artery for 20 minutes. At least 20-min relaxation followed each ligation.

All six selected patients underwent three-graft (one arterial and two autovenous) surgery. During CABG thermology, experiments were performed at various stages of cardiac surgery: after opening of the pericardium, at the time of cardioplegia, and during reperfusion.

Results

In experimental study, we determined that after ligation of the LAD coronary artery, temperature in the ischemic zone of epicardial surface rapidly and progressively decreased by 1–5°C, from 31°C to 28–26°C, respectively. We observed marked temperature anisotropy initially along the coronary artery with subsequent outspread across the whole ventricle (Fig. 1A, B). Immediately after reperfusion, clearly visible system and structure of vessels was observed at the site below the ligation (Fig. 1C). Commonly tissue temperature came back to initial value after 1–3 min on the average. However, exceeded and particularly lower temperature zones were observed during the reperfusion. For more than 5–7 min, in the observed myocardial regions, temperature was lower by 0.8–1.1°C as compared with surrounding tissues (Fig. 1D). It is important that temperature anisotropy of cardiac surface, exceeding 2–3°C, as a rule evoked VF episodes.

Together with experimental measurements, the

changes in temperature of the heart epicardium surface during six CABG operations were recorded. All cardiac surgery procedures were performed with CPB and cold blood cardioplegia. Thermographic images were obtained at various stages of the surgery. Temperatures of ischemic zones as result of significant (>80%) stenosis or occlusion of the LAD coronary artery were recorded after opening of the pericardium before cardioplegia. In cases, when the coronary artery was located not within the heart muscle, it was possible to better evaluate the extent of damage to the coronary artery, characterized by thickening, calcification, or lipid damage of arterial wall, resulting in a decreased blood supply. In one case, the site of occlusion was locally warmer in comparison to surrounding tissues, what could reflect existence of vulnerable plaque activity.

After suturing distal anastomoses of autovenous grafts, thermographic images were obtained. Simultaneously cold cardioplegic solution was injected into the grafts to visualize anastomotic areas and distal parts of coronary vessels. Thermographic images of anastomotic site of internal thoracic artery to LAD coronary artery were obtained just after removing the clamp from the thoracic artery (Fig. 2).

Discussion

Thermographic imaging gives us the possibility for indirect estimation of the dynamic changes in blood flow through coronary arteries and supply of the cardiac tissue. It has been commonly applied in the studies and diagnostics of peripheral vascular diseases, dermatology and oncology practice. Our experimental and clinical data confirm with experimental presentations of Senyk et al. (4), Sakalauskas et al. (5), and clinical report by Siebert (6), who established a correlation between restricted blood flow after LAD coronary artery ligation and temperature anisotropy on the heart epicardial surface. The measurement of temperature allows us to clearly estimate the site and, in some cases, the character of coronary artery lesion. Results of several studies showed that at high risk "vulnerable plaques" have certain characteristics to be more prone to disruption and subsequent thrombosis, which is not a rare fatal complication after CABG surgery (7, 8). Nature, reason, and especially beginning of vulnerable atherosclerotic plaque formation directly responsible of most acute coronary syndromes are often asymptomatic and undetectable by angiography (8). The instability of the plaque core directly correlates with an increase in local temperature. It is an important indicative factor showing that

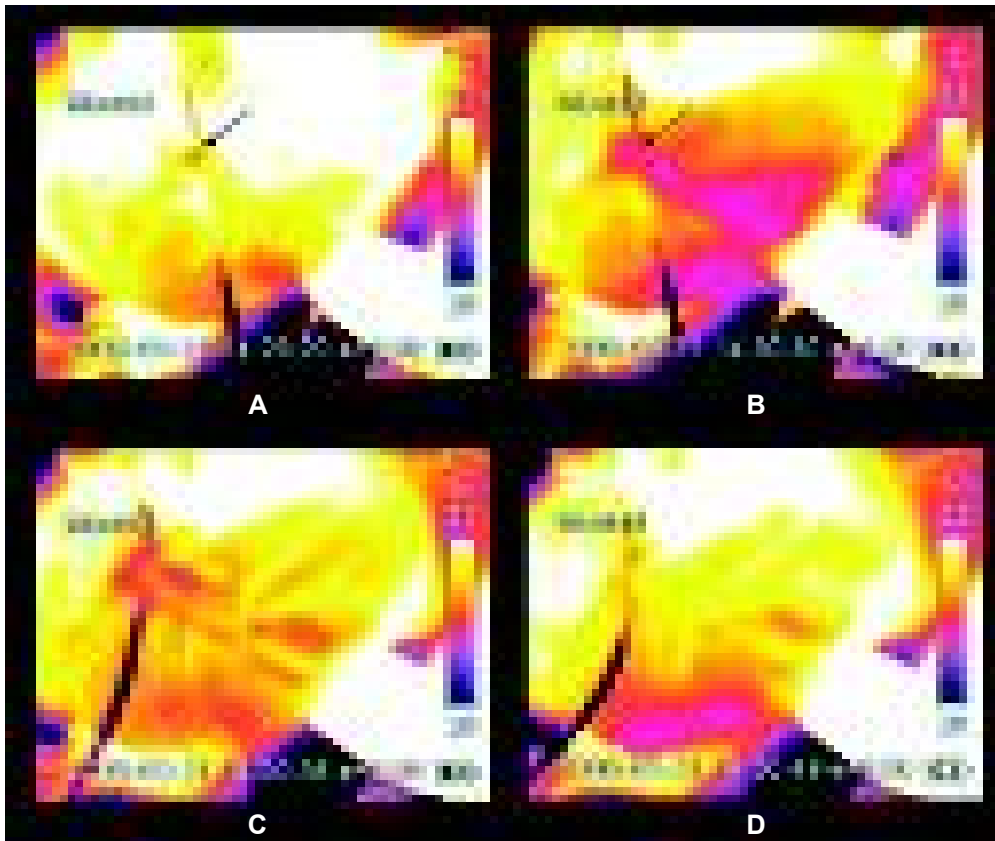


Fig. 1. Thermographic image of the heart tissues after ligation (A, B) and release (C, D) of the left anterior descending coronary artery
Black arrows show the place of ligation.



Fig. 2. Thermographic view of anastomotic areas and distal parts of marginal coronary arteries after suturing autovenous graft

the core became softer and more likely to rupture. Contact-free thermography method could be enough informative approach to detect inflammatory activity at the site of the coronary artery lesion at the time of surgery. Although single cases observed cannot be precondition for strong inference, we believe that with the help of thermography, significant prognostic criteria can be obtained, and it encourages us to continue research and gather experience of its clinical application.

It is of great importance to determine the zone of myocardial ischemic injury, but it is complicated. New features of the development of ischemic process, such as the border zone, are fully visualized by means of thermographic imaging. There are not recent data in literature about imaging of ischemic border zone. However, epicardial border zone can be characterized as site evoking great electrophysiological disturbances – reduced conduction velocity and increased anisotropy of refractory periods (9). These changes are closely associated with the occurrence of reentrant circuits, ventricular tachycardia, or VF (9), which also was observed in our experimental study. Thermography allows us to establish complete site of ischemic injury of myocardium including the border zone, the width of which was approximately 3–7 mm. The tissue temperature in this measurable zone was 1–3°C lower than in normal myocardium. According to our experimental and clinical data, we can agree and confirm the conclusion that border zone significantly modulates the spatial distribution of wave breaks and initiates VF. It could be important for the selection of optimal cardioplegia mode. In cardiac surgery practice, the noninvasive character of thermography is a great advantage. Unlike other methods of visualiza-

tion, thermography can be easily applied without requiring special precautions of foreign contrast agents, and it renders the heart free for surgical procedures throughout the imaging process. Real-time image acquisition at standard video rates enables to see rapid, thermally transient events after cardioplegia, gives an opportunity to visualize temperature dynamics on the beating heart and by this to assess myocardium and graft function (10–13).

The limitations of thermography include problems associated with obtaining appropriated exposition of the same areas located behind the anterior surface of the heart. We had possibility to record temperature changes only from the superficial layers of the heart (1.0–2.0 mm). It is distinctly awkward when the coronary arteries are located within the heart muscle, what is rather than on the surface of the heart, or are covered by lipid layers.

Conclusions

We hope that thermographic imaging of ischemic border zone will be useful in further experimental and clinical studies for better understanding origin of proarrhythmic disturbances in the heart.

On-line thermography may provide additional quantitative information for the surgeon regarding the functional status of the grafts and myocardium and improve outcomes after cardiac surgery.

Acknowledgment

This study was partly supported by the Lithuanian State Science and Studies Foundation project “Development of special data mining methods to explore the anisotropy of texture temperatures of the heart” (No. T-08153).

Širdies audinių temperatūros stebėseną ir nuosruvių funkcijos įvertinimas kardiokirurginių operacijų metu

Raimundas Lekas, Povilas Jakuška, Algimantas Kriščiukaitis, Vincentas Veikutis, Gintautas Dzemyda¹, Tomas Mickevičius, Kristina Morkūnaitė², Alina Vilkė, Povilas Treigys¹, Genuvaitė Civinskienė³, Jonas Andriuškevičius³, Tomas Vanagas³, Kęstutis Skauminas, Jurga Bernatienė³

Kauno medicinos universiteto Biomedicininų tyrimų institutas, ¹Matematikos ir informatikos institutas, Vilnius, ²Kauno medicinos universiteto Kardiologijos institutas, ³Kauno medicinos universitetas

Raktažodžiai: termografija, miokardo išemija, vainikinių arterijų nuosruviai.

Santrauka. Termografija yra bekontaktinis metodas, naudojamas eksperimentuose ir širdies kraujagyslių chirurgijoje miokardo ir vainikinių arterijų funkcijai įvertinti. Formuojant vainikinių arterijų nuosruvius nenaudojant dirbtinės kraujo apytakos, svarbu žinoti, kaip kraujo tėkmės nutraukimas paveikia miokardą ir

kaip po operacijos atsikuria vainikinių arterijų kraujotaka. Mūsų tyrimų objektais eksperimente buvo beveisliai šunys, o klinikoje pacientai, kurių širdys buvo skenuojamos „Agema Thermovision THV 570“ kamera. Gauti duomenys parodė, kad termografija leidžia chirurgui stebėti skilvelinio epikardo paviršiaus temperatūrą norimoje zonoje ir įvertinti kaip funkcionuoja suformuoti nuosruviai. Infraraudonųjų spindulių kamera gali būti naudojama nustatant išeminio miokardo ir širdies kraujagyslių pažeidimo laipsnį kardiokirurginių operacijų metu.

Adresas susirašinėti: V. Veikutis, KMU Biomedicininis tyrimų institutas, Eivenių 4, 50009 Kaunas
El paštas: vincentas.veikutis@med.kmu.lt

References

1. Zaitsev AV, Guha PK, Sarmast F, Kolli A, Berenfeld O, Pertsov AM, et al. Wavebreak formation during ventricular fibrillation in the isolated, regionally ischemic pig heart. *Circ Res* 2003; 92:546-53.
2. Janse MJ, van Capelle FJL, Morsink H, Kleber A, Wilms-Schopman F, Cardinal R, et al. Flow of “injury” current and patterns of excitation during early ventricular arrhythmias in acute regional myocardial ischemia in isolated porcine and canine hearts: evidence for two different arrhythmogenic mechanisms. *Circ Res* 1980;47:151-65.
3. Janse MJ, Downar E. The effect of acute ischemia on transmembrane potentials in the intact heart: the relation to reentrant mechanisms. In: Kulbertus HE, editor. *Reentrant Arrhythmias, Mechanisms and Treatment*. Baltimore, Md: University Park Press; 1977. p. 195-209.
4. Senyk J, Malm A, Bornmyr S. Intraoperative cardiothermography. *Eur Surg Res* 1971;3:1-12.
5. Sakalauskas J, Benetis R, Kriščiukaitis A, Lekas R, Jakuška P. Termografija kardiokirurgijoje. (Thermography in cardiac surgery.) *Medicina (Kaunas)* 2001;37(11):1211-3.
6. Siebert J, Keita L, Kaczmarek M, Anisimowicz L, Rogowski J, Narkiewicz M. Application of intraoperative thermography in coronary bypass grafting without extracorporeal circulation – clinical report. *Med Sci Monit* 2001;7(4):766-70.
7. Coronel R, Wilms-Chopman FJG, Ophof T, Cinca J, Fiolet JWT, Janse MJ. Reperfusion arrhythmias in isolated perfused pig hearts. *Circ Res* 1992;71:1131-42.
8. Nemirovsky D. Imaging of high risk plaque. *Cardiology* 2003; 100:160-75.
9. Yan GX, Joshi A, Guo D, Hlaing T, Martin J, Xu X, et al. Phase 2 reentry as a trigger to initiate ventricular fibrillation during early acute myocardial ischemia. *Circulation* 2004; 110:1036-41.
10. Gordon N, Rispler S, Sideman S, Shofty R, Beyar R. Thermographic imaging in the beating heart: a method for coronary flow estimation based on a heat transfer model. *Med Eng Phys* 1998;20(6):443-51.
11. Kriščiukaitis A, Tamošiūnas M, Veteikis R, Jakuška P, Lekas R, Šaferis V, et al. Evaluation of ischemic injury of the cardiac tissue by using the principal component analysis of an epicardial electrogram. *Comput Methods Programs Biomed* 2006; 82(2):121-9.
12. Mohr FW, Matloff J, Grundfest W, Chau A, Kass R, Blanche C, et al. Thermal coronary angiography: a method for assessing graft patency and coronary anatomy in coronary bypass surgery. *Ann Thorac Surg* 1989;47:441-9.
13. Stanley WC. In vivo models of myocardial metabolism during ischemia: application to drug discovery and evaluation. *J Pharm Tox Meth* 2000;43:133-40.

Received 26 February 2008, accepted 6 March 2009

Straipsnis gautas 2008 02 26, priimtas 2009 03 06