

Investigation of human skin using pulse-echo ultrasonic technique: review and development

R. Raišutis¹, E. Jasiūnienė¹, D. Jasaitienė², S. Valiukevičienė²

1-Ultrasound Institute, Kaunas University of Technology

Studentų Str. 50, Kaunas, LITHUANIA.

Phone: +370 37 351162. Fax: +370 37 451489.

E-mail: renaldas.raisutis@ktu.lt

2- Department of Skin and Venereal Diseases of Kaunas University of Medicine, Lithuania

Abstract

Application of ultrasonic techniques provides non-invasive investigation of a lesion and the possibility to analyze certain aspects of the skin that are inaccessible to the eye of dermatologist. For diagnostic purposes, ultrasound examination makes it possible to recognize lesions causing morphological changes in structure of skin, to localize lesions and their extent, and to measure their thickness and density.

During the literature review it was defined, that an ultrasonic transducer with at least 20 MHz should be applied for effective early stage diagnosis of melanoma. The structure of the skin imaging system including the high frequency ultrasonic data acquisition unit combined with the excitation/reception circuit, mechanics for linear scanning, focused transducer, electronics for scanning control and electronics for estimation of spatial positions has been proposed.

Keywords: malignant melanoma, pulse-echo, ultrasonic technique, sonography

Introduction

Usually, the dermatologists perform the diagnosis and treatment based on a clinical examination. Also, the invasive techniques such as skin biopsy are used for a pathological examination. Application of ultrasonic techniques provides non-invasive investigation within a lesion and the possibility of analyzing the certain aspects of the skin that are inaccessible to the eye of dermatologist and even to histological examination. The image provided by ultrasound depends only on the material characteristics of the skin structure. Ultrasonic examination of the skin has already been used for diagnostic and prognostic purposes in skin diseases. For diagnostic purposes, ultrasound examination makes it possible to recognize the morphological structures of skin, to localize skin lesions and their extent, and to measure their thickness and density. It can be also used in early diagnosis of basal cell carcinomas and melanomas using echographic thickness measurement [1-2]. The principle of human skin assessment by a pulse-echo ultrasonic technique is presented in Fig.1.

High-frequency sonography with mechanical scanners and focused ultrasonic transducers with at least (7.5..20) MHz are widely used for skin thickness and density measurements, also for pre-operative tumour thickness measurement in order to aid in surgical planning. Maximum achievable frequency of commercially available equipment is 100 MHz, however the penetration depth in this case is limited to 1.5 mm. Application of sonography in a dermatologic oncology covers basic diagnostics of potentially metastasizing skin tumours, estimation of the tumour parameters like size, margins and contour, borders to surrounding tissue and internal structure [3-5].

Sentinel and regional lymph node status is an important prognostic factor of skin melanoma. The 5-year relative survival rate of patients with skin melanoma

without detectable lymph node metastasis at the time of diagnosis is more than 75% [6]. For patients with lymph node metastases, the relative 5-year survival rate is less than 50% [6-8]. If the tumour would be detected when its thickness is less than 1.5 mm, more than 85 % of patients would survive. Five-year survival probabilities of patients in relation to the clinical stage of cutaneous melanoma are presented in Table 1 [7, 8].

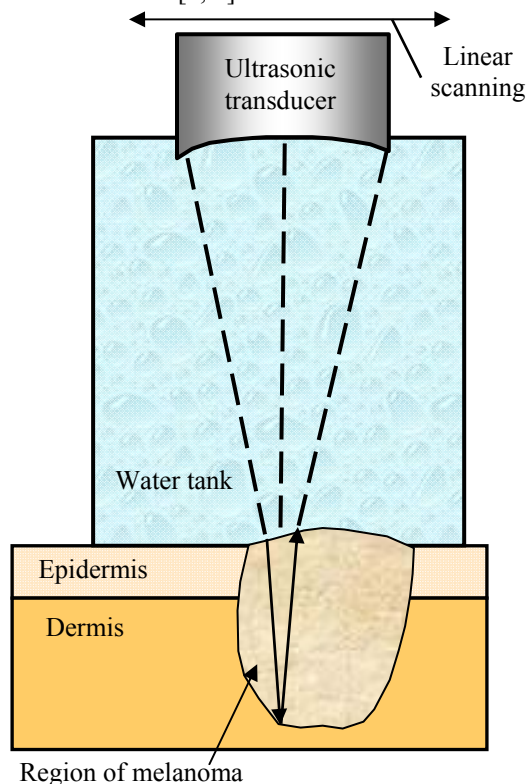


Fig.1. Principle of skin assessment using pulse-echo ultrasonic technique

Table 1. Five-year survival probabilities of patients in relation to the clinical stage of cutaneous melanoma

Clinical stage	Thickness (depth) of the tumour	Probability of five-year survival
I	pT1 (≤ 0.75 mm and/or Clark level II) pT2 (0.76-1.5 mm and/or Clark level III)	95-85 %
II	pT3 (1.51-4.0 mm and /or Clark level IV)	70 %
III	pT4 (> 4.0 mm and/or Clark level V)	50 % <30 %
IV	any pT	<5-10 %

where: pT – pathological thickness (depth) of the tumour measured in mm according to Breslow or Clark

level: I – tumour spread only in the epidermis;

level II – the tumour infiltrates a part of the papillary layer of the dermis;

level III – the tumour invades papillary-reticular dermal interspace;

level IV – the tumour invades the reticular dermis.

When the thickness of melanoma does not reach 0.75 mm, micrometastases are detected in less than 1 % of patients, when the thickness is 0.75-1.5 mm – in 6 % of patients, when the thickness is 1.5-4 mm – in 21 % of patients, and when the tumour is thicker than 4 mm, micrometastases are found in 46 % of patients [8]. Sonography has become extremely helpful for the preoperative assessment of the skin melanoma. When the thickness of the skin melanoma is 1.0 mm or more, it is determined with the help of ultrasound, that the sentinel lymph node (SLN) biopsy must be performed. The Breslow thickness of skin melanoma and micrometastasis in SLN are strong prognostic predictors [8]. The introduction of a sentinel node biopsy in the thick melanoma made the problem of preoperative determination of melanoma thickness crucial. The melanoma thickness of 1 mm was chosen by Pellacani *et al.* as the cut-off point to select cases for sentinel node biopsy because it is still debatable whether this surgical approach should also be used for lesions from 0.75 to 1 mm thick [9].

Histological measurement of the thickness of melanoma is a major prognostic factor and estimates the size of the surgical excision (1 cm for melanomas less than 1 mm thick, 2 cm for melanomas thicker than 2 mm and 3 cm beyond 4 mm). Machet *et al.* has performed a systematic review of surgical margins prediction using ultrasonic techniques. The systematic review of 869 patients study was performed comparing histological and ultrasonic measurements and showing correlation coefficients generally greater than 0.9. The predictive values of adequate margins were in at least 72 % of lesions using preoperative measurement of ultrasonically measured thickness. The average thickness was 1.96 mm measured by an ultrasonic technique and 1.95 mm by histology. It was determined that preoperative high-resolution ultrasound is a non-invasive examination that can help in choosing appropriate surgical margins and could reduce the need of partial or excisional biopsy before surgery and the need for further re-excision also [10].

Ulrich *et al.* have performed study of 249 patients with malignant melanoma using the ultrasonic equipment, frequency of which was 7.5 MHz and 20 MHz. The

comparison of the preoperative vertical tumour thicknesses estimated using the ultrasonic technique to the postoperative tumour thickness determined histomorphometrically was performed. The correspondence of the sonographically with 20 MHz assessed tumour thickness with the thickness assessed by histomorphometry was achieved with a better accuracy ($r = 0.94$) compared to the conventional sonography using 7.5 MHz ($r = 0.76$) [11].

264 patients with a primary malignant melanoma and 417 patients with benign skin tumours were examined by Hoffmann *et al.* using 20 MHz sonography. The final results showed a good correlation between the histological and sonographic estimation of tumour thicknesses ($r = 0.97$) [12]. In order to determine tumour thickness preoperatively the investigation using 20 MHz sonography was performed also by Krahn *et al.* The correlation of the tumour thickness between histometric and sonographic results was determined for nevi ($r = 0.93$) and melanoma ($r = 0.95$); 74.3 % of melanomas were diagnosed correctly within a range of 0.2 mm. Regarding the clinical important limit of 1 mm tumour thickness, 87.2 % were diagnosed in accordance with histometric evaluation [13].

Correlation between sonometric and histometric measurement of tumour invasion depth in 400 patients with a primary malignant melanoma has been estimated close to $r = 0.92$. However, it was concluded that the sonometry was systematically overestimating tumour depth [2]. Also, Guitera *et al.* presented that the ultrasonic technique of 20 MHz tends to overestimate the melanoma Breslow thickness due to lymphocytic infiltration or naevus remnant [14].

From the point of view of dermatology personnel it is expected to determine the size, contour, structure and penetration depth of skin tumours (melanomas) using the pulse-echo ultrasonic technique and to compare the obtained results with those of the clinical and histological examinations. It would be preferable to detect skin tumours in an early stage when thickness of them is less than 1.5 mm.

Limitations of available systems in dermatology

For higher-frequency ultrasonic examinations (> 20 MHz) there are different ultrasound systems available in the market, for example: the Episcan I-200 (Longport, Inc), the DermaScan C (Cortex Technology) and the DUB-USB (Taberna pro medicum).

All ultrasonic transducers of such equipment are scanned mechanically and the coupling liquid is applied in all cases. 2D scanners for B-scan imaging are available in portable configurations for use with handheld ultrasonic transducers. 3D scanners for C-scan imaging, combined with a flexible arm holding the 3D scanning head in which the micro mechanical x-y scanner is mounted, usually are installed into a specialised transportation cart and are not portable. The price of a 3D system is sufficiently high; therefore it is not suitable for physicians - general practisers and small medical offices. Also, only one portable 2D scanning system DUB-USB is assembled as a separate device that can be connected with any PC via USB 2.0 interface. Other portable 2D systems are

combined with PC in the same non-demountable assembly. To our knowledge, the commercially available ultrasonic equipment evaluated during literature review has some limitations from the viewpoint of the investigation of skin thicknesses and structures [15-20]. Usually, only envelope of the signal is being visualized. A large amount of information is lost from the raw radiofrequency (RF) signal. RF signal is not accessible to the user for further processing and analysis using advanced analysis techniques like time – frequency filtering, phase imaging and etc. [19-22]. A small number of scale values usually is being visualized – typically, 256 levels of amplitude (48 dB), only 8 bits. Also, usually the sampling frequency doesn't exceed 100 MHz.

Only 2D (B-scan) imaging in most cases of a portable commercially available and low price equipment is being used. Such imaging does not provide information about the spatial distribution of skin damages like melanomas. No possibility to make the connection with the additional external positioning device of the housing in which the transducer is being scanned and to synchronize the saved data with the appropriate information about the spatial position of a transducer over a human body.

Therefore, it is necessary to develop a more advanced ultrasonic imaging system combined with the appropriate hardware and software to be suitable for early diagnosis of skin melanoma.

Possible structure of more advanced ultrasonic imaging system

Weichenthal *et al* have shown that when a human skin is damaged by melanoma, the mean ultrasound velocity (c) is 1564 m/s [2]. For example, if the assumed thickness (l) of a damaged tissue is 0.1 mm, then the time of flight (TOF) of ultrasonic wave in this part of tissue is $t = (2 \cdot l) / c = 127.9$ ns. Therefore, the deviations of ± 1 % in the ultrasound velocity (± 16 m/s) will give the effect of ± 1.3 ns deviations in TOF. It indicates that it is necessary to use the sampling frequency not less than 200 MHz. In the case when the sampling frequency of 200 MHz is applied, the minimum value of the discretized time interval is $\Delta t = 1/200$ MHz = 5 ns. Hence, the uncertainty of time discretization is $\pm \Delta t / 2 = \pm 2.5$ ns. In order to increase the necessary resolution of TOF measurements even more (close to ± 1 ns) it is necessary to apply the interpolation techniques between the each pair of neighbouring points [23-25].

Also, the sampling frequency of 200 MHz will give the reliable possibility to “extract” information from overlapped reflections [26]. In the case when ultrasonic transducer with the central frequency not less than 20 MHz is used, the maximum bandwidth in the frequency domain should be not less than double value of central frequency.

To overcome the dynamic range limitations of 256 levels of the quantized amplitude and 8 bits of analog to digital converter (ADC), 4096 levels of the quantized amplitude and 12 bits of ADC could be used. In such a

case the dynamic range of quantization will be wider 16 times (24 dB) or more. Possibility to have a wider dynamic range of the quantized amplitude is very important when more advanced RF signal processing algorithms (like time-frequency analysis, phase imaging, filtering and etc.) are used in order to extract the distinctive features of the melanoma and to perform the early diagnosis [19-22].

In order to develop a more advanced ultrasonic imaging system of a human skin, the following tasks should be solved. At first, the focused ultrasonic transducer (>20 MHz) should be developed and optimized. The focused transducer should achieve a sufficiently high axial (close to 80 μ m) and lateral resolution (close to 200 μ m) of multi-layered skin tissue.

The mechanics for linear scanning of the transducer, which should be wear-proof against the long time operation, very precise (scanning step 30 μ m) and in the same way able perform the real time B-scan imaging in a less than second, should be developed. The developed ultrasonic transducer will be installed into the developed mechanics for linear scanning. The electronics of driving / receiving circuits and control of mechanical scanning will be integrated together with the transducer into a single ergonomic assembly. In order to increase the S/N ratio of high frequency ultrasonic signals the appropriate reception circuits should be used. Further, the special manual positioning device with an incorporated incremental encoder should be developed.

The second task is related to the development of the high frequency ultrasonic measurement and data acquisition system in order to control the mechanical scanning of the ultrasonic transducer and appropriate excitation/reception circuits. Such system will be used to get the analog B-scan data at the particular slice of the skin region and to digitize it. Each B-scan will be synchronized with the appropriate value of spatial positioning over a human body (from incremental encoder). The system should have RF input for acquisition of the amplified ultrasonic signals, synchronization (Trigger) output to start the generator /excitation circuit and pulse inputs from the incremental encoder. According to the estimated parameters of similar digitization systems used for medical research in oncology [14-21], the sampling frequency of 200 MHz and ADC with 12 bits, 4096 amplitude levels (72 dB) could be used. The possible structure of ultrasonic imaging system for dermatology is presented in Fig.2.

The appropriate software, suitable to extract the B-scan image from stored raw ultrasonic data should be developed also. Investigation and selection of the ultrasonic signal features, according to which it would be possible to separate healthy tissue from melanoma, should be performed. Finally, the appropriate software and ultrasonic signal processing algorithms for calculation of melanoma contours at different depths and volumetric visualization of the processed 3D ultrasonic data should be developed [19-22].

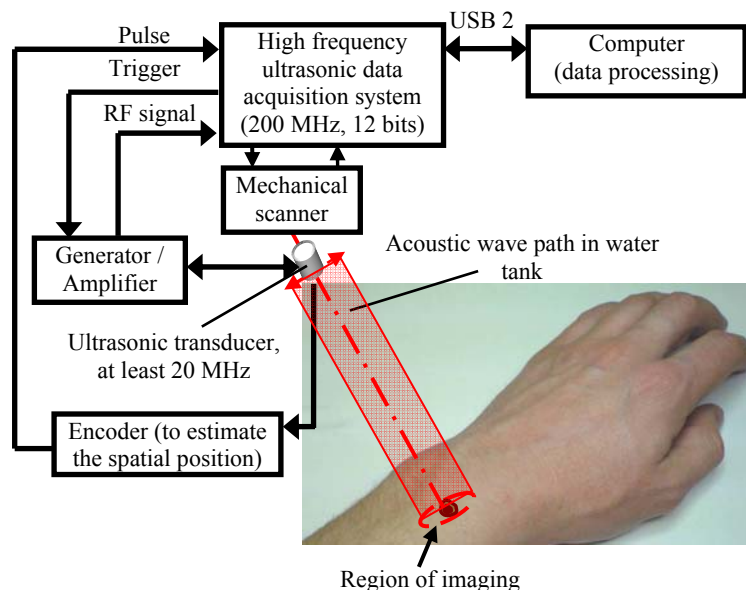


Fig.2. The structure of ultrasonic imaging system for dermatology.

Conclusions

The requirements for the non-invasive ultrasonic investigations of human skin from the dermatologist point of view were defined. It is expected to determine the size, contour, structure and penetration depth of skin tumours in an early stage. It was defined, that the ultrasonic transducer of at least 20 MHz should be applied for an efficient early stage diagnosis of melanoma.

The limitations of the existing in the market ultrasonic diagnostics systems have been discussed and possible structure of a more advanced ultrasonic system was proposed. The structure of the ultrasonic skin imaging system should include the high frequency ultrasonic data acquisition unit combined with the excitation/reception circuit, mechanics for linear scanning, a focused transducer, electronics for scanning control and electronics for estimation of spatial positions.

Acknowledgment

This work was partially sponsored by the Agency for International Science and Technology Development Programmes in Lithuania under the Eurostars project SKINMONITOR "Diagnosis of Skin Cancer Based on Information and Communication Technologies Tools".

References

1. Agache P. G., Humbert P. Measuring the skin. Springer-Verlag. 2004. P.206-214.
2. Weichenthal M., Mohr P. and Breitbart E. W. The velocity of ultrasound in human primary melanoma tissue -implications for the clinical use of high resolution sonography. BMC Dermatology. 2001. 1:1, <http://www.biomedcentral.com/1471-5945/1/1>
3. Dill-Muller D., Maschke J. Ultrasonography in dermatology. JDDG. 2007. Vol. 5. P.689-707.
4. Hein D. W., Moy R. L. Elective lymph node dissection in stage I malignant melanoma: a meta analysis. Melanoma Res. 1992. Vol.2. P.273-277.
5. Schmid-Wendtner M. H., Burgdorf W. Ultrasound scanning in dermatology. Arch Dermatol. 2005. Vol.141. P.217-224.
6. Stang A., Valiukevičienė S., Aleknavičienė B., Kurtinaitis J. Time trends of incidence, mortality and relative survival of invasive skin melanoma in Lithuania. Eur J Cancer. 2006. Vol.42(5). P.660-667.
7. Hantschild A., Christophers E. Sentinel node biopsy in melanoma. Virchows Arch. 2001. Vol.438. P.99-106.
8. Kaikaris V., Valiukevičienė S., Rimdeika R., Gollnick H., Ulrich J. Sentinel lymph node biopsy in melanoma patients: methods, indications, and clinical significance. Medicina. 2003. Vol. 39. No.7. P.621-630.
9. Pellacani G., Seidenari S. Preoperative melanoma thickness determination by 20-MHz sonography and digital videomicroscopy in combination. Arch Dermatol. 2003. Vol 139. P. 293-298.
10. Machet L., Belot V., Naouri M., Boka M., Mourtada Y., Giraudeau B., Laure B., Perrinaud A., Machet M. C., Vaillant L. Preoperative measurement of thickness of cutaneous melanoma using high-resolution 20 MHz ultrasound imaging. A monocenter prospective study and systematic review of the literature. Ultrasound in Medicine & Biology. 2009. Vol. 35. Issue 9. P.1411-1420.
11. Ulrich J., Petereit S., Gollnick H. Preoperative sonographic diagnosis of melanoma – comparison of 7.5- and 20-MHz sonography. Ultraschall Med. 1999. Vol.20. P.197-200.
12. Hoffmann K., Happe M., Schüller S., Stücker M., Wiesner M., Gottlöber P., Schwarz M., Strahler J., Neubauer H., Jung C., Petereit S., Welzel J., Brautzsch N., Bohmeyer J., Wohlrab J., Freitag M., Altmeyer P. Ranking of 20 MHz sonography of malignant melanoma and pigmented lesions in routine diagnosis. Ultraschall Med. Jun 1999. Vol.20(3). P.104-109.
13. Krahn G., Gottlob P., Sander C., Peter R. U. Dermatoscopy and high frequency Sonograp. In Two useful non-invasive methods to increase preoperative diagnostic accuracy in pigmented skin lesions pigment cell Rea. 1998. Vol.11. P.151-154.
14. Guitera P., Li L. X., Crotty K., Fitzgerald P., Mellenbergh R., Pellacani G., Menzies S. W. Melanoma histological Breslow thickness predicted by 75-MHz ultrasonography. Br J Dermatol 2008. Vol.159(2). P.364-369.
15. Lewandowski M., Nowicki A. Versatile high frequency coded imaging system. IEEE Ultrasonic Symposium. 2007. P. 1262-1265.
16. Lewandowski M., Nowicki A. High frequency coded imaging system with RF software signal processing. IEEE transactions on

- ultrasonics, ferroelectrics and frequency control. 2008. Vol.55(8). P.1878-82.
17. **Wilson T., Zagzebski J., Varghese T., Chen Q., Rao M.** The Ultrasonix 500RP: A commercial ultrasound research interface. IEEE transactions on ultrasonics, ferroelectrics, and frequency control. 2006. Vol. 53. No. 10. P.1772-1782.
 18. **Mari J. M., Cachard C.** Acquire real-time RF digital ultrasound data from a commercial scanner. Electronic journal "Technical Acoustics" <http://www.ejta.org>. 2007. Vol.3. P. 1-16.
 19. **Despotovič I. et al.** Using phase information in ultrasound RF-signals for tissue characterization. ProRISC. 2008. P.314-317.
 20. **Paunksnis A., Barzdžiukas V., Kažys R., Raišutis R., Lukoševičius A., Paunksnis M., Janušauskas A., Marozas V., Jegelevičius D., Daukantas S., Kopsala S., Kurapkienė S., Kriaučiūnienė L., Jurkonis R.** A non-invasive expert system for diagnosis of intraocular tumours: the system concept. Ultragarsas (Ultrasound). 2008. Vol. 63. No.4. 66-72.
 21. **Rallan D., Dickson M., Bush N. L., Harland C. C., Mortimer P., Bamber J. C.** High-resolution ultrasound reflex transmission imaging and digital photography: potential tools for the quantitative assessment of pigmented lesions. Skin Research and technology. 2006. Vol.12. P. 50–59.
 22. **Oelze M. L., O'Brien W. D., Blue J. P., Zachary J. F.** Differentiation and characterization of rat mammary fibroadenomas and 4T1 mouse carcinomas using quantitative ultrasound imaging. IEEE Transactions on medical imaging. 2004. Vol. 23. No. 6. P.764-771.
 23. **Raišutis R.** Uncertainty analysis of the ultrasonic thickness measurement of the planar samples. Matavimai (Measurements). ISSN1392-1223. Kaunas: Technologija. 2004. Nr. 2 (30). P. 25-29.
 24. **Kažys R., Raišutis R., Šliteris R., Mažeika L., Jasiūnienė E.** Ultrasonic thickness measurement of the aluminium plate with wavy surface. Ultrasound. ISSN1392-2114. Kaunas: Technologija. 2004. Nr.1.(50). P.11-16.
 25. **Ragauskas A., Daubaris G., Petkus V., Raišutis R., Deksnys V., Guzaitis J.** Ultrasonic time-of-flight method for non-invasive physiological monitoring of the human brain. ISSN 1392-2114 Ultragarsas (Ultrasound). Kaunas: Technologija. 2008 Vol. 63. No. 2. P. 49-52.
 26. **Raišutis R., Kažys R.-J., Mažeika L.** Ultrasonic thickness measurement of multilayered aluminium foam precursor material. IEEE Transactions on instrumentation and measurement. ISSN 0018-9456. 2008. Vol. 57. Iss. 12. P. 2846-2855.

R. Raišutis, E. Jasiūnienė, D. Jasaitienė, S. Valiukevičienė

Žmogaus odos tyrimas taikant ultragarsinį impulso atspindžio metodą: apžvalga ir kūrimas

Reziumė

Ultragarsinis tyrimas – tai neinvazinis odos darinių tyrimas, kurio metu galima analizuoti tuos odos pokyčius, kurie nepastebimi gydytojo dermatovenerologo pirminės apžiūros metu. Jis leidžia atpažinti odos struktūros morfologinius pokyčius, jų pagrindu susiformavusių odos darinių dydį, išplitimo gylį ir tankumą. Atlikus literatūros apžvalgą nustatyta, kad ankstyvų stadijų melanomos diagnostikai geriausiai tinka ne mažesnio kaip 20 MHz dažnio ultragarsinis keitiklis.

Buvo pasiūlyta odos vizualizavimo sistemos struktūra, apimanti aukšto dažnio ultragarsinę duomenų surinkimo sistemą, sujungtą su žadinimo/priėmimo grandine, linijiniam skenavimui tinkamą mechaniką, fokusuotą keitiklį, elektroninį bloką skenavimui valdyti ir elektroninį bloką erdvinėms koordinatėms nustatyti.

Pateikta spaudai 2010 03 17