

World Journal of *Gastroenterology*

World J Gastroenterol 2020 October 14; 26(38): 5745-5910



OPINION REVIEW

- 5745 Role of betaine in liver disease-worth revisiting or has the die been cast?
Mukherjee S
- 5749 Management of an endoscopy center during the outbreak of COVID-19: Experience from West China Hospital
Gao Y, Ye LS, Du J, Zhang QY, Hu B

REVIEW

- 5759 Molecular mechanisms of viral hepatitis induced hepatocellular carcinoma
D'souza S, Lau KC, Coffin CS, Patel TR

MINIREVIEWS

- 5784 Role of artificial intelligence in the diagnosis of oesophageal neoplasia: 2020 an endoscopic odyssey
Hussein M, González-Bueno Puyal J, Mountney P, Lovat LB, Haidry R
- 5797 Gastrointestinal complications after kidney transplantation
Gioco R, Corona D, Ekser B, Puzzo L, Inserra G, Pinto F, Schipa C, Privitera F, Veroux P, Veroux M
- 5812 Is vitamin D receptor a druggable target for non-alcoholic steatohepatitis?
Cao Y, Shu XB, Yao Z, Ji G, Zhang L

ORIGINAL ARTICLE**Basic Study**

- 5822 Acetyl-11-keto- β -boswellic acid inhibits proliferation and induces apoptosis of gastric cancer cells through the phosphatase and tensin homolog / Akt/ cyclooxygenase-2 signaling pathway
Sun MX, He XP, Huang PY, Qi Q, Sun WH, Liu GS, Hua J

Case Control Study

- 5836 Endogenous motion of liver correlates to the severity of portal hypertension
Gelman S, Sakalauskas A, Zyklus R, Pranculis A, Jurkonis R, Kuliavienė I, Lukoševičius A, Kupčinskas L, Kupčinskas J
- 5849 Longitudinal decrease in platelet counts as a surrogate marker of liver fibrosis
Gotlieb N, Schwartz N, Zelber-Sagi S, Chodick G, Shalev V, Shibolet O

Retrospective Study

- 5863 Endoscopic ultrasound-measured muscular thickness of the lower esophageal sphincter and long-term prognosis after peroral endoscopic myotomy for achalasia
Liao Y, Xiao TY, Wu YF, Zhang JJ, Zhang BZ, Wang YD, Wang S, Liu X, Sun SY, Guo JT

Observational Study

- 5874** Monitoring hepatitis C virus treatment rates in an Opioid Treatment Program: A longitudinal study
Sanvisens A, Rivas I, Faure E, Espinach N, Hernandez-Rubio A, Majó X, Colom J, Muga R
- 5884** Comparative study between bowel ultrasound and magnetic resonance enterography among Egyptian inflammatory bowel disease patients
Kamel S, Sakr M, Hamed W, Eltabbakh M, Askar S, Bassuny A, Hussein R, Elbaz A

META-ANALYSIS

- 5896** Tacrolimus and mycophenolate mofetil as second-line treatment in autoimmune hepatitis: Is the evidence of sufficient quality to develop recommendations?
Abdollahi M, Ekrami NK, Ghojazadeh M, Boezen HM, Somi M, Alizadeh BZ

ABOUT COVER

Editorial Board Member of *World Journal of Gastroenterology*, Gordon Stanley Howarth, PhD, BSc, RCPA is a tenured Professor in Gastrointestinal Physiology at the School of Animal and Veterinary Sciences, University of Adelaide (Australia). Professor Howarth was appointed as an inaugural scientist at South Australia's Child Health Research Institute in 1989. He was awarded a Cancer Council South Australia Research Fellowship in 2005, subsequently being awarded the nationally-competitive Sally Birch Cancer Council Australia Senior Research Fellowship in Cancer Control (2009) and a South Australian Cancer Council Collaborative Senior Research Fellowship in 2012. Professor Howarth has published more than 170 journal articles on novel nutraceutical treatments for gastrointestinal disease and holds an Affiliate Professor appointment in the Gastroenterology Department of Adelaide's Women's and Children's Hospital. (L-Editor: Filipodia)

AIMS AND SCOPE

The primary aim of *World Journal of Gastroenterology* (*WJG*, *World J Gastroenterol*) is to provide scholars and readers from various fields of gastroenterology and hepatology with a platform to publish high-quality basic and clinical research articles and communicate their research findings online. *WJG* mainly publishes articles reporting research results and findings obtained in the field of gastroenterology and hepatology and covering a wide range of topics including gastroenterology, hepatology, gastrointestinal endoscopy, gastrointestinal surgery, gastrointestinal oncology, and pediatric gastroenterology.

INDEXING/ABSTRACTING

The *WJG* is now indexed in Current Contents®/Clinical Medicine, Science Citation Index Expanded (also known as SciSearch®), Journal Citation Reports®, Index Medicus, MEDLINE, PubMed, PubMed Central, and Scopus. The 2020 edition of Journal Citation Report® cites the 2019 impact factor (IF) for *WJG* as 3.665; IF without journal self cites: 3.534; 5-year IF: 4.048; Ranking: 35 among 88 journals in gastroenterology and hepatology; and Quartile category: Q2.

RESPONSIBLE EDITORS FOR THIS ISSUE

Production Editor: Yan-Liang Zhang; Production Department Director: Yun-Xiaojuan Wu; Editorial Office Director: Ze-Mao Gong.

NAME OF JOURNAL

World Journal of Gastroenterology

ISSN

ISSN 1007-9327 (print) ISSN 2219-2840 (online)

LAUNCH DATE

October 1, 1995

FREQUENCY

Weekly

EDITORS-IN-CHIEF

Andrzej S Tarnawski, Subrata Ghosh

EDITORIAL BOARD MEMBERS

<http://www.wjgnet.com/1007-9327/editorialboard.htm>

PUBLICATION DATE

October 14, 2020

COPYRIGHT

© 2020 Baishideng Publishing Group Inc

INSTRUCTIONS TO AUTHORS

<https://www.wjgnet.com/bpg/gerinfo/204>

GUIDELINES FOR ETHICS DOCUMENTS

<https://www.wjgnet.com/bpg/GerInfo/287>

GUIDELINES FOR NON-NATIVE SPEAKERS OF ENGLISH

<https://www.wjgnet.com/bpg/gerinfo/240>

PUBLICATION ETHICS

<https://www.wjgnet.com/bpg/GerInfo/288>

PUBLICATION MISCONDUCT

<https://www.wjgnet.com/bpg/gerinfo/208>

ARTICLE PROCESSING CHARGE

<https://www.wjgnet.com/bpg/gerinfo/242>

STEPS FOR SUBMITTING MANUSCRIPTS

<https://www.wjgnet.com/bpg/GerInfo/239>

ONLINE SUBMISSION

<https://www.f6publishing.com>

Case Control Study

Endogenous motion of liver correlates to the severity of portal hypertension

Sigita Gelman, Andrius Sakalauskas, Romanas Zykus, Andrius Pranculis, Rytis Jurkonis, Irma Kuliavienė, Arūnas Lukoševičius, Limas Kupčinskas, Juozas Kupčinskas

ORCID number: Sigita Gelman 0000-0002-7324-1425; Andrius Sakalauskas 0000-0002-3978-7301; Romanas Zykus 0000-0001-7204-0106; Andrius Pranculis 0000-0002-3772-0867; Rytis Jurkonis 0000-0002-9481-1773; Irma Kuliavienė 0000-0002-1392-8954; Arūnas Lukoševičius 0000-0002-9268-5347; Limas Kupčinskas 0000-0002-8689-9023; Juozas Kupčinskas 0000-0002-8760-7416.

Author contributions: Kupcinskas L and Kupcinskas J designed the research; Gelman S, Zykus R and Kuliavienė I treated patients, collected material and clinical data from the patients; Sakalauskas A, Jurkonis R and Lukosevicius A analyzed the radiofrequency signals and developed the algorithm; Pranculis A performed hepatic vein catheterization and HVPG measurement; Gelman S performed ultrasound scanning, analysed the data and drafted the manuscript; Kupcinskas J approved the final version of the manuscript.

Supported by the Research Council of Lithuania, No. S-MIP-19-8; and the Research, Development and Innovation Fund of Kaunas University of Technology, No. MTEPI-L-17003 and MTEPI-L-16012.

Sigita Gelman, Romanas Zykus, Irma Kuliavienė, Department of Gastroenterology, Medical Academy, Lithuanian University of Health Sciences, Kaunas 44307, Lithuania

Andrius Sakalauskas, Rytis Jurkonis, Arūnas Lukoševičius, Biomedical Engineering Institute, Kaunas University of Technology, Kaunas 51423, Lithuania

Andrius Pranculis, Department of Radiology, Medical Academy, Lithuanian University of Health Sciences, Kaunas 44307, Lithuania

Limas Kupčinskas, Juozas Kupčinskas, Institute for Digestive Research and Department of Gastroenterology, Medical Academy, Lithuanian University of Health Sciences, Kaunas 44307, Lithuania

Corresponding author: Sigita Gelman, MD, PhD, Assistant Lecturer, Attending Doctor, Department of Gastroenterology, Medical Academy, Lithuanian University of Health Sciences, A. Mickevičiaus Str. 9, Kaunas 44307, Lithuania. sigita.gelman@ismuni.lt

Abstract

BACKGROUND

Degree of portal hypertension (PH) is the most important prognostic factor for the decompensation of liver cirrhosis and death, therefore adequate care for patients with liver cirrhosis requires timely detection and evaluation of the presence of clinically significant PH (CSPH) and severe PH (SPH). As the most accurate method for the assessment of PH is an invasive direct measurement of hepatic venous pressure gradient (HVPG), the search for non-invasive methods to diagnose these conditions is actively ongoing.

AIM

To evaluate the feasibility of parameters of endogenously induced displacements and strain of liver to assess degree of PH.

METHODS

Of 36 patients with liver cirrhosis and measured HVPG were included in the case-control study. Endogenous motion of the liver was characterized by derived parameters of region average tissue displacement signal (d_{antero} , dr_{etro} , d_{RMS}) and results of endogenous tissue strain imaging using specific radiofrequency signal processing algorithm. Average endogenous strain μ and standard deviation σ of

Institutional review board

statement: The study was reviewed and approved by the Kaunas Region Biomedical Research Ethics Committee (2015-08-24, No. BE-2-28, Kaunas, Lithuania).

Informed consent statement: All study participants provided informed written consent prior to study enrollment.

Conflict-of-interest statement: None declared.

Data sharing statement: Technical appendix and dataset available from the corresponding author at sigita.gelman@lsmuni.lt. Informed consent for data sharing was not obtained but the presented data are anonymized, and risk of identification is low.

STROBE statement: The authors have read the STROBE Statement – checklist of items, and the manuscript was prepared and revised according to the STROBE Statement – checklist of items.

Open-Access: This article is an open-access article that was selected by an in-house editor and fully peer-reviewed by external reviewers. It is distributed in accordance with the Creative Commons Attribution NonCommercial (CC BY-NC 4.0) license, which permits others to distribute, remix, adapt, build upon this work non-commercially, and license their derivative works on different terms, provided the original work is properly cited and the use is non-commercial. See: <http://creativecommons.org/licenses/by-nc/4.0/>

Manuscript source: Unsolicited manuscript

Received: May 21, 2020

Peer-review started: May 21, 2020

First decision: May 29, 2020

Revised: June 11, 2020

Accepted: September 17, 2020

Article in press: September 17, 2020

Published online: October 14, 2020

P-Reviewer: Sun G

strain were assessed in the regions of interest (ROI) (1 cm × 1 cm and 2 cm × 2 cm in size) and different frequency subbands of endogenous motion (0-10 Hz and 10-20 Hz).

RESULTS

Four parameters showed statistically significant ($P < 0.05$) correlation with HVPG measurement. The strongest correlation was obtained for the standard deviation of strain (estimated at 0-10 Hz and 2 cm × 2 cm ROI size). Three parameters showed statistically significant differences between patient groups with CSPH, but only d_{retro} showed significant results in SPH analysis. According to ROC analysis area under the curve (AUC) of the $\sigma_{\text{ROI}[0...10\text{Hz}, 2\text{cm} \times 2\text{cm}]}$ parameter reached 0.71 ($P = 0.036$) for the diagnosis of CSPH; with a cut-off value of 1.28 $\mu\text{m}/\text{cm}$ providing 73% sensitivity and 70% specificity. AUC for the diagnosis of CSPH for $\mu_{\text{ROI}[0...10\text{Hz}, 1\text{cm} \times 1\text{cm}]}$ was 0.78 ($P = 0.0024$); with a cut-off value of 3.92 $\mu\text{m}/\text{cm}$ providing 73% sensitivity and 80% specificity. D_{retro} parameter had an AUC of 0.86 ($P = 0.0001$) for the diagnosis of CSPH and 0.84 ($P = 0.0001$) for the diagnosis of SPH. A cut-off value of -132.34 μm yielded 100% sensitivity for both conditions, whereas specificity was 80% and 72% for CSPH and SPH respectively.

CONCLUSION

The parameters of endogenously induced displacements and strain of the liver correlated with HVPG and might be used for non-invasive diagnosis of PH.

Key Words: Portal hypertension; Endogenous motion; Strain elastography; Hepatic venous pressure gradient; Radiofrequency parameters

©The Author(s) 2020. Published by Baishideng Publishing Group Inc. All rights reserved.

Core Tip: In this study, we aimed to evaluate the feasibility of parameters of endogenously induced displacements and strain of the liver to assess the degree of portal hypertension. Endogenous motion of the liver was characterized by derived parameters of region average tissue displacement signal and results of endogenous tissue strain imaging using specific radiofrequency signal processing algorithm. Our proposed parameters correlated with hepatic venous pressure gradient and statistically significant differences were observed between patient groups with clinically significant and severe portal hypertension. To our knowledge it is the first study to evaluate prognostic potential of endogenous motion parameters to detect clinically significant and severe portal hypertension.

Citation: Gelman S, Sakalauskas A, Zykyus R, Pranculis A, Jurkonis R, Kuliavienė I, Lukoševičius A, Kupčinskas L, Kupčinskas J. Endogenous motion of liver correlates to the severity of portal hypertension. *World J Gastroenterol* 2020; 26(38): 5836-5848

URL: <https://www.wjgnet.com/1007-9327/full/v26/i38/5836.htm>

DOI: <https://dx.doi.org/10.3748/wjg.v26.i38.5836>

INTRODUCTION

The burden of chronic liver diseases is growing and decompensated liver cirrhosis is responsible for a million of deaths per year worldwide^[1]. The grade of portal hypertension (PH) expressed by hepatic venous pressure gradient (HVPG) is an important prognostic factor for the decompensation of liver cirrhosis and formation of life threatening complications, such as ascites, gastroesophageal varices and hepatic encephalopathy^[2,3]. HVPG value greater than 5 mmHg is considered to be PH. Clinically significant PH (CSPH) is diagnosed when HVPG values exceed 10 mmHg and is associated with the formation of gastroesophageal varices, ascites and hepatorenal syndrome. When HVPG values exceed 12 mmHg severe PH (SPH) is diagnosed with higher risk of variceal bleeding and decompensation. Thus the evaluation of the presence of CSPH and SPH are of utmost importance^[4,5].

Direct measurement of HVPG is regarded as the most accurate method for the assessment of PH, however this procedure is currently reserved for specialized centers, as it is invasive, costly and requires expertise^[2,6].

S-Editor: Yan JP

L-Editor: A

P-Editor: Zhang YL



Ultrasound elastography is one of the most widely used non-invasive alternatives for the diagnosis of PH. The method is appealing due to its low cost, applicability and availability^[4,7]. Several ultrasound elastography techniques have been developed: Strain imaging [strain elastography (SE), using internal/external compression stimuli, or acoustic radiation force impulse] and shear wave imaging [point shear wave elastography (pSWE), 2D-SWE and transient elastography (TE)]^[8,9]. Out of existing ultrasound elastography techniques TE, using Fibroscan (Echosens, France), has shown most promising results in diagnosing CSPH with area under the receiver operating characteristic curve (AUROC) of 0.90, sensitivity 87% and specificity 85%, whereas other shear wave techniques showed lower sensitivity in this field^[10-12]. The readings of TE, pSWE and 2D-SWE are affected by active inflammation, cholestasis, fatty liver and biliary obstruction thus TE performance is not optimal in patients with obesity, ascites, narrow intercostal space. These limitations encourage the search for another alternative technique that could be applied in this diverse patient population.

SE is an ultrasound elastography technique widely used for the examination of musculoskeletal system^[13], breast and thyroid pathologies^[14], however it has been scarcely evaluated in the setting of liver cirrhosis and PH. SE measures axial displacement of tissue caused by manual compression or physiological shifts inside the body (cardiovascular pulsatility or breathing)^[15,16]. Elasticity is displayed as color coded elastograms: Areas with lower strain are displayed in blue and areas with higher strain in red^[11,15]. The drawback of this technique is that it measures the strain of tissues and the resulting elastogram is not quantifiable^[16]. To obtain more accurate and reproducible results various semi-quantitative methods have been developed^[15]. Different scores for semi-quantitative interpretation of SE have been proposed: The German Elasticity Score, the Japanese Elasticity Score, the LF Index, calculation of strain^[9,17]. Other research groups develop and apply specific algorithms for quantitative evaluation of elasticity using a number of statistical parameters, derived from the distribution of recorded strains within a region of interest (ROI). The key parameters are: Mean strain, standard deviation of the mean; the percentage of blue area; complexity of the blue areas^[18-23]. One advantage of this technique is the ability to evaluate the inhomogeneity of strain in larger areas of the liver^[24,25]. Also, what is more important, SE readings are not affected by hepatic inflammation, jaundice, liver congestion, fatty degeneration, obesity, ascites or narrow intercostal spaces as is the case with other elastography modalities^[15,26-28].

Studies concerning SE performance in PH are scarce. Ochi *et al*^[29] reported that SE was useful for the diagnosis of PH in patients with non-alcoholic liver disease. Hirooka *et al*^[30] evaluated SE performance in CSPH and SPH using elastic ratio. In their study AUROC for the diagnosis of CSPH was 0.83 and for the diagnosis of SPH - 0.78.

Our group has applied SE technique to assess the strain of liver tissue caused by endogenous motion of the beating heart and developed a specific radiofrequency (RF) signal analysis algorithm to calculate the parameters for quantification of strain in liver tissue. We have previously applied this RF ultrasound-based tissue strain imaging method to characterize tissue elasticity *in vitro*^[31] and demonstrated the feasibility of this method in diagnosing liver fibrosis in patients with hepatitis C virus^[32]. The aim of present study was to evaluate the ability and feasibility of endogenously induced displacements and strain on the liver to assess the degree of PH, using this specifically developed RF signal analysis algorithm.

MATERIALS AND METHODS

Patients

Patients with hepatitis C virus and/or alcohol induced liver cirrhosis, hospitalized for the HVPG measurement procedure to the Hospital of Lithuanian University of Health Sciences, Department of Gastroenterology were included in this study. Exclusion criteria were: Pre- or post-hepatic causes of PH, cardiovascular disease, current use of beta-blockers or other vasoactive drugs, presence of ascites. Demographic data, medical history, aetiology of liver disease and HVPG values were recorded. The diagnosis of liver cirrhosis was based on clinical, laboratory and radiologic data and/or histology.

The study was approved by Kaunas Region Biomedical Research Ethics Committee (2015-08-24, No. BE-2-28, Kaunas, Lithuania) and a written informed consent to participate in the study was acquired from all participants.

Ultrasound scanning

We collected data using ultrasound scanner Ultrasonix Sonix Touch (Analogic Ultrasound, Canada), which allows to collect raw RF signals of all scanning lines. The ultrasound scanning was performed on the day of HVPG measurement prior to the procedure. Scanning protocol and the main RF data acquisition parameters were described in previous paper^[32].

HVPG measurement

Invasive HVPG measurement procedure was used to assess the degree of PH. The procedure was performed according to standard as described by previous authors^[33]. Portal pressure was considered to be normal for HVPG values of 1-5 mmHg. When HVPG values exceeded 6 mmHg, PH was diagnosed. HVPG values of ≥ 10 mmHg represented clinically significant and ≥ 12 mmHg – SPH.

RF signal processing

Endogenous motion of the liver was characterized by derived parameters of region average tissue displacement signal and results of endogenous tissue strain imaging.

Displacement estimation

The displacements along the scanning beam line were estimated applying cross-correlation based technique. The signals were interpolated before calculation of cross-correlation. Length of the correlation window was set to 6 wavelengths and the overlap was 50%. The detailed description of the method could be found in previous publication^[32]. The sequences of displacement images were obtained as a result of the displacement estimation stage.

Displacement parameters

The user predefined regions of interest (ROI) in all images of displacements were averaged in space, thus obtaining the region average liver tissue displacement signal. The average displacement signal could be expressed as follows:

Formula 1 where $p = 1 \dots P$, P – number of displacement data points in a ROI of a subsector, $d_p[k]$ – displacement signal at p -th spatial position in a ROI, $k = 1 \dots K$, K – acquisition instance (frame number).

Afterwards, the motion of the liver was characterized by three parameters of the region average tissue displacement signal (assessment example is presented in **Figure 1A**): (1) Maximal amplitude of motion towards the ultrasonic probe d_{antero} ; (2) Maximal amplitude of motion backwards from the ultrasonic probe d_{retro} ; and (3) Average level of motion by root-mean-square d_{RMS} value:

Formula 2 where $k = 1 \dots K$, K – acquisition instance (frame number).

Strain parameters

The endogenous strain map was derived from the temporal sequence of the displacement images. The strain maps were obtained taking the gradient of integrated spectral coefficient. An example of derived strain map is presented in **Figure 1B**. The description of data processing methods used for parametric imaging of endogenous strain was presented in detail in previous study^[32].

The local quantitative assessment of the strain was performed by analyzing the distribution of derived strain map values in user predefined rectangular ROI of constant size (see assessment example in **Figure 1B**). The investigation was performed in 2 frequency subbands (integration ranges for lower f_1 and f_2 frequencies 0-10 Hz and higher 10-20 Hz, respectively) and 2 sizes of ROI (1 cm \times 1 cm and 2 cm \times 2 cm). The ROI selection criteria were based on visual evaluation of B scans and the obtained endogenous strain maps. At first, the sequences of B mode images were carefully revised with the aim to identify appropriate regions. The regions that contained only liver parenchyma without clearly visible blood vessels in B scans were outlined by the observer in the spatially corresponding images of endogenous strain.

All 11 investigated parameters of endogenous motion of liver together with a description are provided in **Table 1**.

Statistical analysis

Statistical analysis was performed using SPSS 25.0 and Medcalc softwares. Kolmogorov-Smirnov test was used to check data normality. Descriptive statistics are provided as median and range for non-parametric data. Patients were divided into groups according to HVPG values: (1) Patients without CSPH (HVPG < 10 mmHg); (2)

Table 1 Investigated endogenous motion parameters

No.	Parameter	Description
1	d_{antero}	Maximal amplitude of endogenous displacements towards the probe, μm
2	d_{retro}	Maximal amplitude of the displacements backward, μm
3	d_{RMS}	Average level of motion, μm
4	$\mu_{\text{ROI}[0...10 \text{ Hz}, 2 \text{ cm} \times 2 \text{ cm}]}$	Average strain [estimated for the 0...10 Hz sub-band of endogenous motion in the 2 cm \times 2 cm ROI], $\mu\text{m}/\text{cm}$
5	$\sigma_{\text{ROI}[0...10 \text{ Hz}, 2 \text{ cm} \times 2 \text{ cm}]}$	Standard deviation of strain [0...10 Hz, 2 cm \times 2 cm], $\mu\text{m}/\text{cm}$
6	$\mu_{\text{ROI}[0...10 \text{ Hz}, 1 \text{ cm} \times 1 \text{ cm}]}$	Average strain [0...10 Hz, 1 cm \times 1 cm], $\mu\text{m}/\text{cm}$
7	$\sigma_{\text{ROI}[0...10 \text{ Hz}, 1 \text{ cm} \times 1 \text{ cm}]}$	Standard deviation of strain [0...10 Hz, 1 cm \times 1 cm], $\mu\text{m}/\text{cm}$
8	$\mu_{\text{ROI}[10...20 \text{ Hz}, 2 \text{ cm} \times 2 \text{ cm}]}$	Average strain [10...20 Hz, 2 cm \times 2 cm], $\mu\text{m}/\text{cm}$
9	$\sigma_{\text{ROI}[10...20 \text{ Hz}, 2 \text{ cm} \times 2 \text{ cm}]}$	Standard deviation of strain [10...20 Hz, 2 cm \times 2 cm], $\mu\text{m}/\text{cm}$
10	$\mu_{\text{ROI}[10...20 \text{ Hz}, 1 \text{ cm} \times 1 \text{ cm}]}$	Average strain [10...20 Hz, 1 cm \times 1 cm], $\mu\text{m}/\text{cm}$
11	$\sigma_{\text{ROI}[10...20 \text{ Hz}, 1 \text{ cm} \times 1 \text{ cm}]}$	Standard deviation of strain [10...20 Hz, 1 cm \times 1 cm], $\mu\text{m}/\text{cm}$

ROI: Region of interest; RMS: Root mean square.

$$\overline{d[k]} = \frac{1}{P} \cdot \sum_{p=1}^P d_p[k]$$

Formula 1

Patients with CSPH (HVPG ≥ 10 mmHg); (3) Patients without SPH (HVPG < 12 mmHg); and (4) Patients with SPH (HVPG ≥ 12 mmHg). Differences between the groups were evaluated using the Mann-Whitney's test. Correlations were performed using Spearman's correlation and expressed by Spearman's coefficient. ROC curves were created to assess the predictive values of RF parameters for the degree of PH. AUC, sensitivity, specificity, positive predictive value (PPV) and negative predictive value (NPV) were calculated. The cut-off value according to Youden's index was chosen for the analysis of RF parameters. Statistical significance was established at $P < 0.05$.

RESULTS

Of 36 patients were included in the study. Mean age (\pm SD) of the subjects was 54.25 ± 8.82 ; 58.3% were male. Hepatitis C induced liver cirrhosis was diagnosed in 63.9% of cases. The summary of the demographic data is presented in [Table 2](#).

We determined the correlation between the investigated strain parameters and invasive HPV measurement. Spearman's correlation coefficient (ρ) values and P value for the assessment of statistical significance are presented in [Table 3](#). Four parameters showed statistically significant ($P < 0.05$) correlation with HVPG measurement. The strongest correlation was obtained for the standard deviation of strain (estimated at 0-10 Hz integration range and 2 cm \times 2 cm ROI size). The directions of correlations met the expectation in almost all the cases. Negative correlation confirmed that the derived strain estimates decreased with an increment of HVPG.

In the next stage we investigated the ability of these four parameters to evaluate CSPH (HVPG ≥ 10 mmHg) and SPH (HVPG ≥ 12 mmHg). The results are presented in boxplots as median and interquartile ranges ([Figure 2](#) and [3](#)). Three parameters (No. 2, 5, 6; [Table 1](#)) showed statistically significant differences between the groups.

According to ROC analysis d_{retro} parameter had an AUC of 0.86 ($P = 0.0001$) for the diagnosis of CSPH and 0.84 ($P = 0.0001$) for the diagnosis of SPH. A cut-off value of -132.34 μm yielded 100% sensitivity for both conditions, whereas specificity was 80% and 72% for CSPH and SPH respectively ([Figure 4](#)). AUC of the $\sigma_{\text{ROI}[0...10 \text{ Hz}, 2 \text{ cm} \times 2 \text{ cm}]}$

Table 2 Demographic and clinical data of the patients

Variable	Characteristics (n = 36)
Sex (male/female; %)	58.3/41.7
Age (yr; SD)	54.25 (8.82)
Aethiology (% of patients)	
Alcohol cirrhosis	36.1
HCV cirrhosis	63.9
Child-Pugh score (A/B/C; % of patients)	58.3/36.2/5.6
HVPG (mmHg; SD)	14.3 (5.9)
HVPG 1-5 mmHg (% of patients)	2.8
HVPG 6-9 mmHg (% of patients)	25
CSPH; HVPG \geq 10 mmHg (% of patients)	72.2
SPH; HVPG \geq 12 mmHg (% of patients)	69.4

HCV: Hepatitis C virus; HVPG: Hepatic venous pressure gradient; CSPH: Clinically significant portal hypertension; SPH: Severe portal hypertension.

Table 3 Correlations between the investigated parameters and hepatic venous pressure gradient

No.	Parameter	Spearman's ρ	P value
1	d_{antero}	-0.31	0.07
2	d_{retro}	0.34	0.04
3	d_{RMS}	-0.33	0.05
4	$\mu_{\text{ROI}}[0...10 \text{ Hz}, 2 \times 2 \text{ cm}]$	-0.38	0.04
5	$\sigma_{\text{ROI}}[0...10 \text{ Hz}, 2 \text{ cm} \times 2 \text{ cm}]$	-0.42	0.01
6	$\mu_{\text{ROI}}[0...10 \text{ Hz}, 1 \text{ cm} \times 1 \text{ cm}]$	-0.38	0.02
7	$\sigma_{\text{ROI}}[0...10 \text{ Hz}, 1 \text{ cm} \times 1 \text{ cm}]$	-0.27	0.11
8	$\mu_{\text{ROI}}[10...20 \text{ Hz}, 2 \text{ cm} \times 2 \text{ cm}]$	-0.19	0.28
9	$\sigma_{\text{ROI}}[10...20 \text{ Hz}, 2 \text{ cm} \times 2 \text{ cm}]$	-0.14	0.43
10	$\mu_{\text{ROI}}[10...20 \text{ Hz}, 1 \text{ cm} \times 1 \text{ cm}]$	-0.16	0.34
11	$\sigma_{\text{ROI}}[10...20 \text{ Hz}, 1 \text{ cm} \times 1 \text{ cm}]$	-0.16	0.36

ROI: Region of interest; RMS: Root mean square.

parameter reached 0.71 ($P = 0.036$) for the diagnosis of CSPH; with a cut-off value of 1.28 $\mu\text{m}/\text{cm}$ providing 73% sensitivity and 70% specificity. AUC for the diagnosis of CSPH for $\mu_{\text{ROI}}[0...10\text{Hz}, 1 \text{ cm} \times 1 \text{ cm}]$ was 0.78 ($P = 0.0024$); with a cut-off value of 3.92 $\mu\text{m}/\text{cm}$ providing 73% sensitivity and 80% specificity (Figure 5). Data on specificity, sensitivity, PPV and NPV are presented in Table 4.

DISCUSSION

Diagnosis of PH is currently based on the invasive procedure requiring high expertise; therefore, the need for an accurate non-invasive diagnostic test is growing. In this study for the non-invasive diagnosis of PH we applied a RF ultrasound-based tissue strain imaging method. We have shown that four out of 11 investigated parameters significantly correlated with HVPG and predicted CSPH and SPH. The d_{retro} parameter was a strong predictor of CSPH and SPH with sensitivity and NPV of 100%. Other authors have described similar performance in non-invasive diagnosis of CSPH of TE^[34], whereas pSWE and 2D SWE methods were less sensitive (AUC 0.85 and 0.81

Table 4 Diagnostic performance of parameters for the diagnosis of portal hypertension

Parameter	Value	Sensitivity	Specificity	PPV	NPV	P value
d_{retro}						
CSPH	132.34 μm	100	80	93	100	0.0001
SPH		100	72	89	100	0.0001
$\sigma_{ROI}[0...10 \text{ Hz}, 2 \text{ cm} \times 2 \text{ cm}]$						
CSPH	1.28 $\mu\text{m}/\text{cm}$	73	70	86	50	0.036
$\mu_{ROI}[0...10 \text{ Hz}, 1 \text{ cm} \times 1 \text{ cm}]$						
CSPH	3.92 $\mu\text{m}/\text{cm}$	73	80	90	53	0.0024

CSPH: Clinically significant portal hypertension; SPH: Severe portal hypertension; PPV: Positive predictive value; NPV: Negative predictive value; ROI: Region of interest.

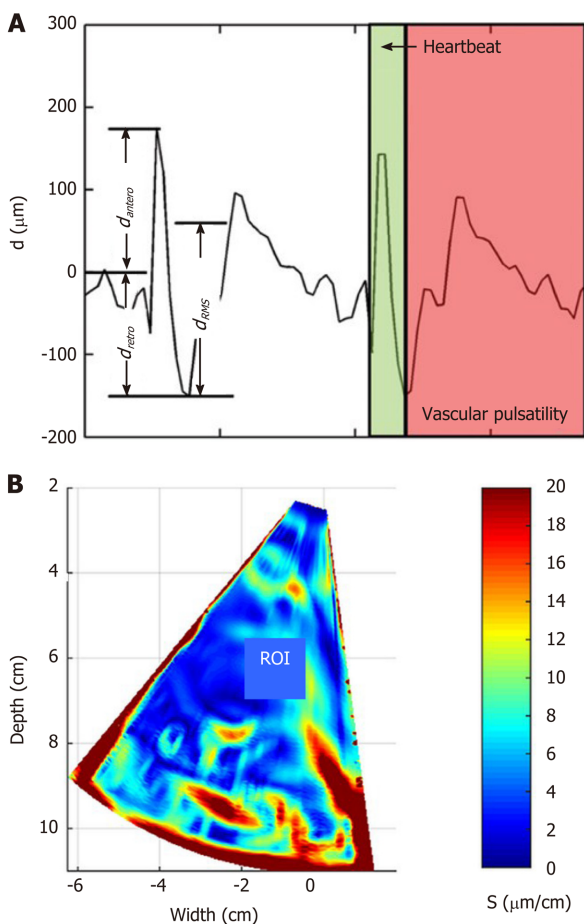


Figure 1 Example illustrating assessment of the endogenous liver displacements and strain. A: region averaged tissue displacement signal obtained in the subsector at time interval (2...3.8) s (three parameters of region averaged displacement signal d_{RMS} , d_{antero} and d_{retro} were evaluated in this study); B: the obtained strain map [amplitude coded in ($\mu\text{m}/\text{cm}$)] together with regions of interest (red rectangle, size 1 cm \times 1 cm) used for the local assessment of endogenous strain. ROI: Regions of interest.

respectively, sensitivity 71% and 85% respectively^[35,36].

The presented technique has certain limitations. It does not allow the evaluation of strain in real-time differently from commercial SE techniques and the strain parameters are calculated retrospectively, using recorded RF data. The other limitation of the approach is the detection of displacements field only in the direction of ultrasound wave propagation. Our method reveals the estimates of the displacements and strain only in single projection of endogenous motion, which is actually three-dimensional. The second projection of motion could be estimated by updating the

$$d_{RMS} = \sqrt{\frac{1}{K} \cdot \sum_{k=1}^K d^2[k]}$$

Formula 2

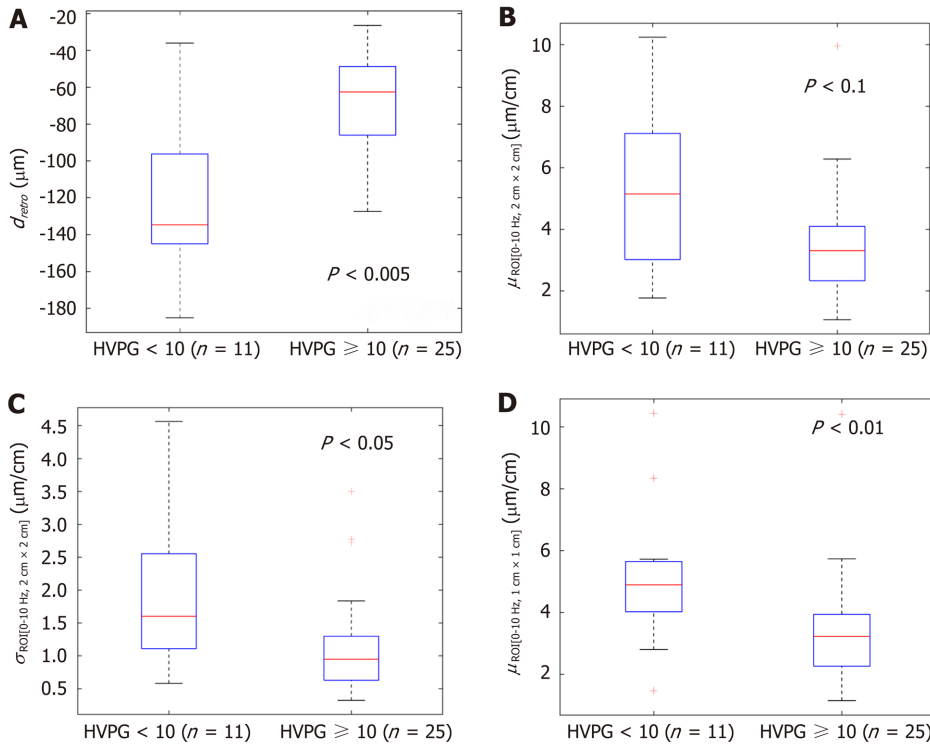


Figure 2 The boxplots and *P* values representing the derived parameters of endogenous displacements and strain in patients with and without clinically significant portal hypertension (≥ 10 mmHg). A: d_{retro} ; B: $\mu_{ROI}[0...10Hz, 2\text{ cm} \times 2\text{ cm}]$; C: $\sigma_{ROI}[0...10Hz, 2\text{ cm} \times 2\text{ cm}]$; D: $\mu_{ROI}[0...10Hz, 1\text{ cm} \times 1\text{ cm}]$. HVPG: Hepatic venous pressure gradient.

algorithm for two-dimensional detection, but sector shaped scan requires complicated computations.

In this method we have used an undefined endogenous source for the tissue displacement excitation, which might influence quantified evaluation of liver elasticity. The endogenous motion also has a complex pattern which is composed from the very slow waves, induced by respiratory activity, a bit faster vascular pulsatility and relatively fast mechanical strain induced by the heartbeat and motion artefacts. However, the exact definition of motion inducing sources is beyond this study and will be investigated in future research. Other technical limitations of the method were disclosed in the previous study^[32]. Also, despite the promising results, this was a pilot study and our results could be biased by the small size of our sample.

CONCLUSION

In conclusion, the parameters of endogenously induced displacements and strain of the liver significantly correlated with HVPG and could be a potential diagnostic tool for the non-invasive diagnosis of PH. A proposed method is potentially suitable for other applications of non-invasive diagnostics.

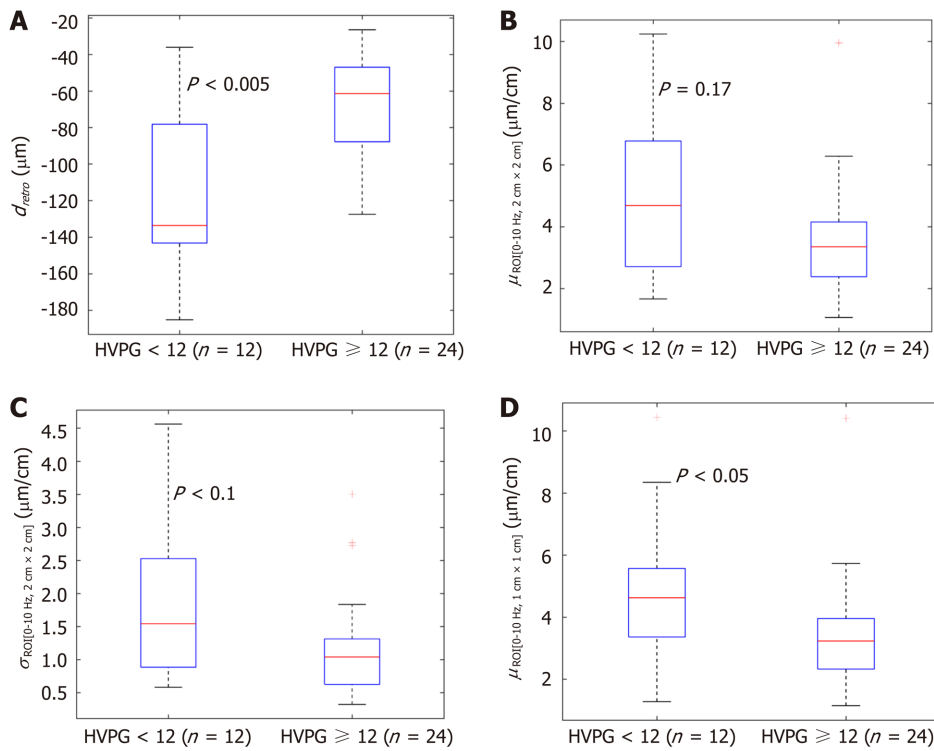


Figure 3 The boxplots and P values representing the derived parameters of endogenous displacements and strain in patients with and without severe portal hypertension (≥ 12 mmHg). A: d_{retro} ; B: $\mu_{\text{ROI}[0...10\text{Hz}, 2\text{cm} \times 2\text{cm}]}$; C: $\sigma_{\text{ROI}[0...10\text{Hz}, 2\text{cm} \times 2\text{cm}]}$; D: $\mu_{\text{ROI}[0...10\text{Hz}, 1\text{cm} \times 1\text{cm}]}$. HVPG: Hepatic venous pressure gradient.

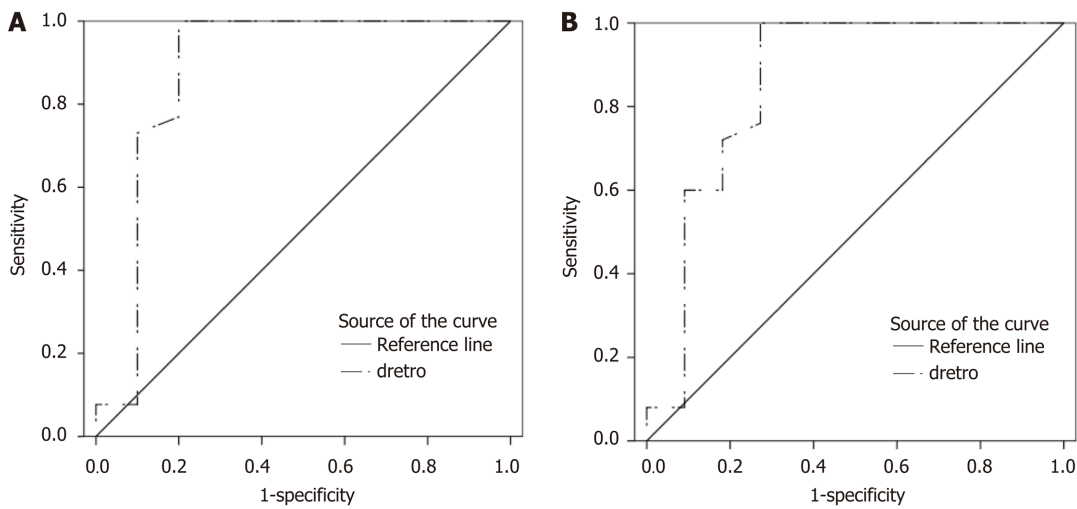


Figure 4 Receiver operating characteristic curves of d_{retro} parameter for the diagnosis of portal hypertension. A: Receiver operating characteristic (ROC) curve for clinically significant portal hypertension [hepatic venous pressure gradient (HVPG) ≥ 10 mmHg]; B: ROC curve for severe portal hypertension (HVPG ≥ 12 mmHg).

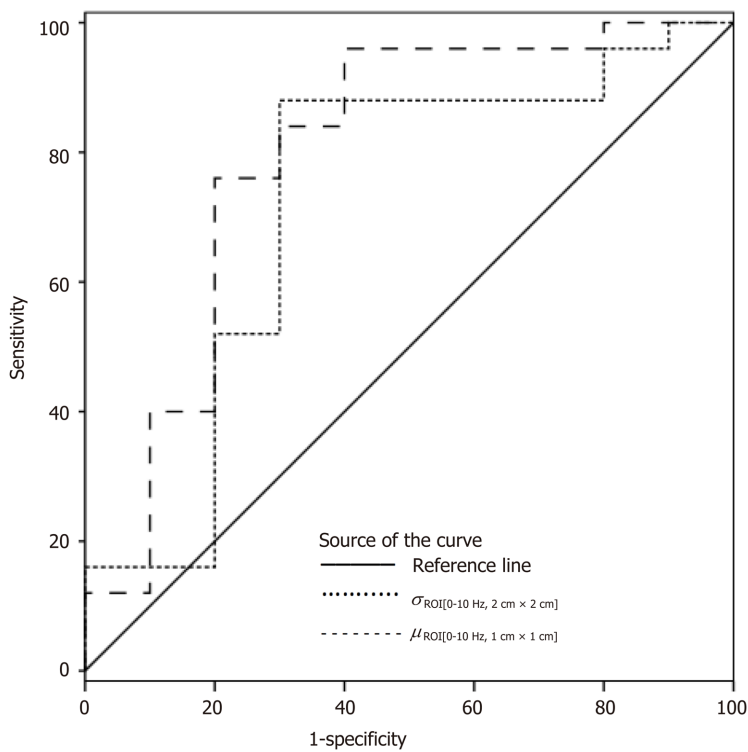


Figure 5 Receiver operating characteristic curves of $\sigma_{\text{ROI}[0-10\text{ Hz}, 2\text{ cm} \times 2\text{ cm}]}$ and $\mu_{\text{ROI}[0-10\text{ Hz}, 1\text{ cm} \times 1\text{ cm}]}$ parameters for the diagnosis of clinically significant portal hypertension (hepatic venous pressure gradient ≥ 10 mmHg).

ARTICLE HIGHLIGHTS

Research background

Degree of portal hypertension (PH) is the most important prognostic factor for the decompensation of liver cirrhosis and death, therefore adequate care for patients with liver cirrhosis requires timely detection and evaluation of the presence of clinically significant PH (CSPH) and severe PH (SPH).

Research motivation

As the most accurate method for the assessment of PH is an invasive direct measurement of hepatic venous pressure gradient (HVPG), the search for non-invasive methods to diagnose these conditions is actively ongoing. Ultrasound elastography is one of the most widely used non-invasive alternatives for the diagnosis of PH. Strain elastography (SE) is an ultrasound elastography technique widely used for the examination of musculoskeletal system, breast and thyroid pathologies, however it has been scarcely evaluated in the setting of liver cirrhosis and PH. It is an appealing alternative, as it is considered that SE readings are not affected by hepatic inflammation, jaundice, liver congestion, fatty degeneration, obesity, ascites or narrow intercostal spaces as is the case with other elastography modalities.

Research objectives

Our group has applied SE technique to assess the strain of liver tissue caused by endogenous motion of the beating heart and developed a specific radiofrequency (RF) signal analysis algorithm to calculate the parameters for quantification of strain in liver tissue. The aim of present study was to evaluate the ability and feasibility of endogenously induced displacements and strain on the liver to assess the degree of PH, using this specifically developed RF signal analysis algorithm.

Research methods

Of 36 patients with liver cirrhosis and measured HVPG were included in the case-control study. Endogenous motion of the liver was characterized by derived parameters of region average tissue displacement signal (d_{antero} , d_{retro} , d_{RMS}) and results of endogenous tissue strain imaging using specific radiofrequency signal processing algorithm. Average endogenous strain μ and standard deviation σ of strain were

assessed in the regions of interest (ROI) (1 cm × 1 cm and 2 cm × 2 cm in size) and different frequency subbands of endogenous motion (0-10 Hz and 10-20 Hz).

Research results

Four parameters showed statistically significant ($P < 0.05$) correlation with HVPG measurement. The strongest correlation was obtained for the standard deviation of strain (estimated at 0-10 Hz and 2 cm × 2 cm ROI size). Three parameters showed statistically significant differences between patient groups with CSPH, but only d_{retro} showed significant results in SPH analysis. According to ROC analysis area under the curve (AUC) of the $\sigma_{\text{ROI}[0...10\text{Hz}, 2\text{ cm} \times 2\text{ cm}]}$ parameter reached 0.71 ($P = 0.036$) for the diagnosis of CSPH; with a cut-off value of 1.28 $\mu\text{m}/\text{cm}$ providing 73% sensitivity and 70% specificity. AUC for the diagnosis of CSPH for $\mu_{\text{ROI}[0...10\text{Hz}, 1\text{ cm} \times 1\text{ cm}]}$ was 0.78 ($P = 0.0024$); with a cut-off value of 3.92 $\mu\text{m}/\text{cm}$ providing 73% sensitivity and 80% specificity. D_{retro} parameter had an AUC of 0.86 ($P = 0.0001$) for the diagnosis of CSPH and 0.84 ($P = 0.0001$) for the diagnosis of SPH. A cut-off value of -132.34 μm yielded 100% sensitivity for both conditions, whereas specificity was 80% and 72% for CSPH and SPH respectively.

Research conclusions

The parameters of endogenously induced displacements and strain of the liver significantly correlated with HVPG. This shows that parameters of endogenous motion could be a potential diagnostic tool for the non-invasive diagnosis of PH. A proposed method is potentially suitable for other applications of non-invasive diagnostics.

Research perspectives

The presented technique has certain limitations. It does not allow the evaluation of strain in real-time differently from commercial SE techniques and the strain parameters are calculated retrospectively, using recorded RF data. The other limitation of the approach is the detection of displacements field only in the direction of ultrasound wave propagation. In this method we have used an undefined endogenous source for the tissue displacement excitation, which might influence quantified evaluation of liver elasticity. Also despite the promising results, this was a pilot study and our results could be biased by the small size of our sample. We are conducting further research of this method, which will include larger groups of patients, also allowing subgroup analysis of patients with ascites and obesity.

REFERENCES

- 1 Marcellin P, Kutala BK. Liver diseases: A major, neglected global public health problem requiring urgent actions and large-scale screening. *Liver Int* 2018; **38** Suppl 1: 2-6 [PMID: 29427496 DOI: 10.1111/liv.13682]
- 2 Snowdon VK, Guha N, Fallowfield JA. Noninvasive evaluation of portal hypertension: emerging tools and techniques. *Int J Hepatol* 2012; **2012**: 691089 [PMID: 22720166 DOI: 10.1155/2012/691089]
- 3 Silkauskaitė V, Kupčinskas J, Pranculis A, Jonaitis L, Petrenkienė V, Kupčinskas L. Acute and 14-day hepatic venous pressure gradient response to carvedilol and nebivolol in patients with liver cirrhosis. *Medicina (Kaunas)* 2013; **49**: 467-473 [PMID: 24823927 DOI: 10.3390/medicina49110073]
- 4 Ravaioli F, Montagnani M, Lisotti A, Festi D, Mazzella G, Azzaroli F. Noninvasive Assessment of Portal Hypertension in Advanced Chronic Liver Disease: An Update. *Gastroenterol Res Pract* 2018; **2018**: 4202091 [PMID: 29977287 DOI: 10.1155/2018/4202091]
- 5 Marozas M, Zykyus R, Sakalauskas A, Kupčinskas L, Lukoševičius A. Noninvasive Evaluation of Portal Hypertension Using a Supervised Learning Technique. *J Healthc Eng* 2017; **2017**: 6183714 [PMID: 29158886 DOI: 10.1155/2017/6183714]
- 6 Thabut D, Moreau R, Lebre C. Noninvasive assessment of portal hypertension in patients with cirrhosis. *Hepatology* 2011; **53**: 683-694 [PMID: 21274889 DOI: 10.1002/hep.24129]
- 7 Sigrist RMS, Liau J, Kaffas AE, Chammas MC, Willmann JK. Ultrasound Elastography: Review of Techniques and Clinical Applications. *Theranostics* 2017; **7**: 1303-1329 [PMID: 28435467 DOI: 10.7150/thno.18650]
- 8 Shiina T, Nightingale KR, Palmeri ML, Hall TJ, Bamber JC, Barr RG, Castera L, Choi BI, Chou YH, Cosgrove D, Dietrich CF, Ding H, Amy D, Farrokh A, Ferraioli G, Filice C, Friedrich-Rust M, Nakashima K, Schafer F, Sporea I, Suzuki S, Wilson S, Kudo M. WFUMB guidelines and recommendations for clinical use of ultrasound elastography: Part 1: basic principles and terminology. *Ultrasound Med Biol* 2015; **41**: 1126-1147 [PMID: 25805059 DOI: 10.1016/j.ultrasmedbio.2015.03.009]
- 9 Dietrich CF, Bamber J, Berzigotti A, Bota S, Cantisani V, Castera L, Cosgrove D, Ferraioli G, Friedrich-Rust M, Gilja OH, Goertz RS, Karlas T, de Knecht R, de Ledinghen V, Piscaglia F, Procopet B, Saftoiu A, Sidhu PS, Sporea I, Thiele M. EFSUMB Guidelines and Recommendations on the Clinical Use of Liver Ultrasound Elastography, Update 2017 (Long Version). *Ultraschall Med* 2017; **38**: e48 [PMID: 30176678]

- DOI: [10.1055/a-0641-0076](https://doi.org/10.1055/a-0641-0076)]
- 10 **Shi KQ**, Fan YC, Pan ZZ, Lin XF, Liu WY, Chen YP, Zheng MH. Transient elastography: a meta-analysis of diagnostic accuracy in evaluation of portal hypertension in chronic liver disease. *Liver Int* 2013; **33**: 62-71 [PMID: [22973991](https://pubmed.ncbi.nlm.nih.gov/22973991/) DOI: [10.1111/liv.12003](https://doi.org/10.1111/liv.12003)]
 - 11 **Şirli R**, Sporea I, Popescu A, Dănilă M. Ultrasound-based elastography for the diagnosis of portal hypertension in cirrhotics. *World J Gastroenterol* 2015; **21**: 11542-11551 [PMID: [26556985](https://pubmed.ncbi.nlm.nih.gov/26556985/) DOI: [10.3748/wjg.v21.i41.11542](https://doi.org/10.3748/wjg.v21.i41.11542)]
 - 12 **Zyklus R**, Jonaitis L, Petrenkienė V, Pranculis A, Kupčinskas L. Liver and spleen transient elastography predicts portal hypertension in patients with chronic liver disease: a prospective cohort study. *BMC Gastroenterol* 2015; **15**: 183 [PMID: [26702818](https://pubmed.ncbi.nlm.nih.gov/26702818/) DOI: [10.1186/s12876-015-0414-z](https://doi.org/10.1186/s12876-015-0414-z)]
 - 13 **Kim SJ**, Park HJ, Lee SY. Usefulness of strain elastography of the musculoskeletal system. *Ultrasonography* 2016; **35**: 104-109 [PMID: [26810195](https://pubmed.ncbi.nlm.nih.gov/26810195/) DOI: [10.14366/usg.15072](https://doi.org/10.14366/usg.15072)]
 - 14 **Cosgrove D**, Piscaglia F, Bamber J, Bojunga J, Correas JM, Gilja OH, Klauser AS, Sporea I, Calliada F, Cantisani V, D'Onofrio M, Drakonaki EE, Fink M, Friedrich-Rust M, Fromageau J, Havre RF, Jenssen C, Ohlinger R, Săftoiu A, Schaefer F, Dietrich CF; EFSUMB. EFSUMB guidelines and recommendations on the clinical use of ultrasound elastography. Part 2: Clinical applications. *Ultraschall Med* 2013; **34**: 238-253 [PMID: [23605169](https://pubmed.ncbi.nlm.nih.gov/23605169/) DOI: [10.1055/s-0033-1335375](https://doi.org/10.1055/s-0033-1335375)]
 - 15 **Kudo M**, Shiina T, Moriyasu F, Iijima H, Tateishi R, Yada N, Fujimoto K, Morikawa H, Hirooka M, Sumino Y, Kumada T. JSUM ultrasound elastography practice guidelines: liver. *J Med Ultrason (2001)* 2013; **40**: 325-357 [PMID: [27277450](https://pubmed.ncbi.nlm.nih.gov/27277450/) DOI: [10.1007/s10396-013-0460-5](https://doi.org/10.1007/s10396-013-0460-5)]
 - 16 **Carlsen JF**, Ewertsen C, Lönn L, Nielsen MB. Strain Elastography Ultrasound: An Overview with Emphasis on Breast Cancer Diagnosis. *Diagnostics (Basel)* 2013; **3**: 117-125 [PMID: [26835671](https://pubmed.ncbi.nlm.nih.gov/26835671/) DOI: [10.3390/diagnostics3010117](https://doi.org/10.3390/diagnostics3010117)]
 - 17 **Sandulescu L**, Rogoveanu I, Gheonea IA, Cazacu S, Saftoiu A. Real-time elastography applications in liver pathology between expectations and results. *J Gastrointest Liver Dis* 2013; **22**: 221-227 [PMID: [23799224](https://pubmed.ncbi.nlm.nih.gov/23799224/)]
 - 18 **Dietrich CF**, Barr RG, Farrok A, Dìghe M, Hocke M, Jenssen C, Dong Y, Saftoiu A, Havre RF. Strain Elastography - How To Do It? *Ultrasound Int Open* 2017; **3**: E137-E149 [PMID: [29226273](https://pubmed.ncbi.nlm.nih.gov/29226273/) DOI: [10.1055/s-0043-119412](https://doi.org/10.1055/s-0043-119412)]
 - 19 **Wu T**, Ren J, Cong SZ, Meng FK, Yang H, Luo Y, Lin HJ, Sun Y, Wang XY, Pei SF, Zheng Y, He Y, Chen Y, Hu Y, Yang N, Li P, Kudo M, Zheng RQ. Accuracy of real-time tissue elastography for the evaluation of hepatic fibrosis in patients with chronic hepatitis B: a prospective multicenter study. *Dig Dis* 2014; **32**: 791-799 [PMID: [25376298](https://pubmed.ncbi.nlm.nih.gov/25376298/) DOI: [10.1159/000368024](https://doi.org/10.1159/000368024)]
 - 20 **Morikawa H**, Fukuda K, Kobayashi S, Fujii H, Iwai S, Enomoto M, Tamori A, Sakaguchi H, Kawada N. Real-time tissue elastography as a tool for the noninvasive assessment of liver stiffness in patients with chronic hepatitis C. *J Gastroenterol* 2011; **46**: 350-358 [PMID: [20697747](https://pubmed.ncbi.nlm.nih.gov/20697747/) DOI: [10.1007/s00535-010-0301-x](https://doi.org/10.1007/s00535-010-0301-x)]
 - 21 **Mobarak L**, Nabeel MM, Hassan E, Omran D, Zakaria Z. Real-time elastography as a noninvasive assessment of liver fibrosis in chronic hepatitis C Egyptian patients: a prospective study. *Ann Gastroenterol* 2016; **29**: 358-362 [PMID: [27366038](https://pubmed.ncbi.nlm.nih.gov/27366038/) DOI: [10.20524/aog.2016.0033](https://doi.org/10.20524/aog.2016.0033)]
 - 22 **Friedrich-Rust M**, Ong MF, Herrmann E, Dries V, Samaras P, Zeuzem S, Sarrazin C. Real-time elastography for noninvasive assessment of liver fibrosis in chronic viral hepatitis. *AJR Am J Roentgenol* 2007; **188**: 758-764 [PMID: [17312065](https://pubmed.ncbi.nlm.nih.gov/17312065/) DOI: [10.2214/AJR.06.0322](https://doi.org/10.2214/AJR.06.0322)]
 - 23 **Ge L**, Shi B, Song YE, Li Y, Wang S, Wang X. Clinical value of real-time elastography quantitative parameters in evaluating the stage of liver fibrosis and cirrhosis. *Exp Ther Med* 2015; **10**: 983-990 [PMID: [26622426](https://pubmed.ncbi.nlm.nih.gov/26622426/) DOI: [10.3892/etm.2015.2628](https://doi.org/10.3892/etm.2015.2628)]
 - 24 **Thiele M**, Kjaergaard M, Thielsen P, Krag A. Contemporary use of elastography in liver fibrosis and portal hypertension. *Clin Physiol Funct Imaging* 2017; **37**: 235-242 [PMID: [26459184](https://pubmed.ncbi.nlm.nih.gov/26459184/) DOI: [10.1111/cpf.12297](https://doi.org/10.1111/cpf.12297)]
 - 25 **Piscaglia F**, Marinelli S, Bota S, Serra C, Venerandi L, Leoni S, Salvatore V. The role of ultrasound elastographic techniques in chronic liver disease: current status and future perspectives. *Eur J Radiol* 2014; **83**: 450-455 [PMID: [23891139](https://pubmed.ncbi.nlm.nih.gov/23891139/) DOI: [10.1016/j.ejrad.2013.06.009](https://doi.org/10.1016/j.ejrad.2013.06.009)]
 - 26 **Koizumi Y**, Hirooka M, Abe M, Tokumoto Y, Yoshida O, Watanabe T, Nakamura Y, Imai Y, Yukimoto A, Kumagi T, Takeshita E, Ikeda Y, Hiasa Y. Comparison between real-time tissue elastography and vibration-controlled transient elastography for the assessment of liver fibrosis and disease progression in patients with primary biliary cholangitis. *Hepatol Res* 2017; **47**: 1252-1259 [PMID: [28044427](https://pubmed.ncbi.nlm.nih.gov/28044427/) DOI: [10.1111/hepr.12861](https://doi.org/10.1111/hepr.12861)]
 - 27 **Sporea I**, Gilja OH, Bota S, Şirli R, Popescu A. Liver elastography - an update. *Med Ultrason* 2013; **15**: 304-314 [PMID: [24286095](https://pubmed.ncbi.nlm.nih.gov/24286095/) DOI: [10.11152/mu.2013.2066.154.isp23](https://doi.org/10.11152/mu.2013.2066.154.isp23)]
 - 28 **Wu T**, Wang P, Zhang T, Zheng J, Li S, Zeng J, Kudo M, Zheng R. Comparison of Two-Dimensional Shear Wave Elastography and Real-Time Tissue Elastography for Assessing Liver Fibrosis in Chronic Hepatitis B. *Dig Dis* 2016; **34**: 640-649 [PMID: [27750231](https://pubmed.ncbi.nlm.nih.gov/27750231/) DOI: [10.1159/000448825](https://doi.org/10.1159/000448825)]
 - 29 **Ochi H**, Hirooka M, Koizumi Y, Miyake T, Tokumoto Y, Soga Y, Tada F, Abe M, Hiasa Y, Onji M. Real-time tissue elastography for evaluation of hepatic fibrosis and portal hypertension in nonalcoholic fatty liver diseases. *Hepatology* 2012; **56**: 1271-1278 [PMID: [22488593](https://pubmed.ncbi.nlm.nih.gov/22488593/) DOI: [10.1002/hep.25756](https://doi.org/10.1002/hep.25756)]
 - 30 **Hirooka M**, Ochi H, Koizumi Y, Kisaka Y, Abe M, Ikeda Y, Matsuura B, Hiasa Y, Onji M. Splenic elasticity measured with real-time tissue elastography is a marker of portal hypertension. *Radiology* 2011; **261**: 960-968 [PMID: [21926379](https://pubmed.ncbi.nlm.nih.gov/21926379/) DOI: [10.1148/radiol.11110156](https://doi.org/10.1148/radiol.11110156)]
 - 31 **Sakalauskas A**, Jurkonis R, Gelman S, Lukoševičius A, Kupčinskas L. Development of radiofrequency ultrasound based method for elasticity characterization using low frequency endogenous motion: Phantom study. In: Eskola H, Väisänen O, Viik J, Hyttinen J, editors. EMBEC & NBC 2017: IFMBE Proceedings; 2017 June 13. Singapore: Springer, 2017; 65 [DOI: [10.1007/978-981-10-5122-7_119](https://doi.org/10.1007/978-981-10-5122-7_119)]
 - 32 **Sakalauskas A**, Jurkonis R, Gelman S, Lukoševičius A, Kupčinskas L. Investigation of Radiofrequency Ultrasound-Based Fibrotic Tissue Strain Imaging Method Employing Endogenous Motion. *J Ultrasound Med* 2019; **38**: 2315-2327 [PMID: [30609066](https://pubmed.ncbi.nlm.nih.gov/30609066/) DOI: [10.1002/jum.14925](https://doi.org/10.1002/jum.14925)]
 - 33 **Groszmann RJ**, Wongcharatrawee S. The hepatic venous pressure gradient: anything worth doing should be

- done right. *Hepatology* 2004; **39**: 280-282 [PMID: [14767976](#) DOI: [10.1002/hep.20062](#)]
- 34 **Song J**, Ma Z, Huang J, Luo Y, Zykus R, Kumar A, Kitson M, Lu Q. Reliability of Transient Elastography-Based Liver Stiffness for Diagnosing Portal Hypertension in Patients with Alcoholic Liver Disease: A Diagnostic Meta-Analysis with Specific Cut-Off Values. *Ultraschall Med* 2020; **41**: 60-68 [PMID: [30616265](#) DOI: [10.1055/a-0731-0178](#)]
- 35 **Salzl P**, Reiberger T, Ferlitsch M, Payer BA, Schwengerer B, Trauner M, Peck-Radosavljevic M, Ferlitsch A. Evaluation of portal hypertension and varices by acoustic radiation force impulse imaging of the liver compared to transient elastography and AST to platelet ratio index. *Ultraschall Med* 2014; **35**: 528-533 [PMID: [24871695](#) DOI: [10.1055/s-0034-1366506](#)]
- 36 **Kim TY**, Jeong WK, Sohn JH, Kim J, Kim MY, Kim Y. Evaluation of portal hypertension by real-time shear wave elastography in cirrhotic patients. *Liver Int* 2015; **35**: 2416-2424 [PMID: [25875718](#) DOI: [10.1111/liv.12846](#)]



Published by **Baishideng Publishing Group Inc**
7041 Koll Center Parkway, Suite 160, Pleasanton, CA 94566, USA
Telephone: +1-925-3991568
E-mail: bpgoffice@wjgnet.com
Help Desk: <https://www.f6publishing.com/helpdesk>
<https://www.wjgnet.com>

