

# Application of Ultrasound Spectral Analysis for Choroidal Melanomas Before and After Treatment Analysis

Jurgis TRUMPAITIS<sup>1,2</sup>, Rytis JURKONIS<sup>3</sup>,  
Ieva SAKALAUŠKAITĖ<sup>1</sup>, Alvydas PAUNKSNIS<sup>1,4</sup>

<sup>1</sup> Department of Ophthalmology, Lithuanian University of Health Sciences, Medicine Academy, Kaunas, Lithuania,

<sup>2</sup> Department of Ophthalmology, Neuroscience Institute, Ophthalmology laboratory, Kaunas, Lithuania,

<sup>3</sup> Institute for Biomedical Engineering, Kaunas University of Technology, Kaunas, Lithuania,  
<sup>4</sup> JSC “Stratelus”, Vilnius, Lithuania

j.trumpaitis@gmail.com, rytis.jurkonis@ktu.lt,  
iewaskl@gmail.com, alvydas@stratelus.com

**Abstract.** Choroidal Melanoma (CM) is the most common primary malignancy of the eye. The overall incidence is approximately 5–7 cases per million per year. In this paper the new technique for tumours tissue structure evaluation using ultrasound spectral analysis is presented. Based on the obtained results, it can be said that radio frequency (RF) ultrasound signals parameters at the healthy tissue area and the area with the intraocular tumour – melanoma before and after treatment statistically are significantly different. This study has shown that the lower amplitude, lower spectral intercept, high spectral slope and high momentary bandwidth are typical for choroidal melanoma if compared with healthy tissues and the lower momentary bandwidth are typical for choroidal melanoma after treatment if compared with melanoma before treatment. Application of spectral analysis using non-invasive ultrasound expert system, provides the new opportunities in early diagnosis, differentiation of tumours, evaluation of the treatment effectiveness.

**Keywords:** ultrasound, intraocular tumours, choroidal melanoma, spectral analysis, radiofrequency signals, brachytherapy.

## 1. Introduction

### 1.1 Choroidal melanoma diagnosis and prevalence

Uveal melanoma (UM) is the most common primary intraocular malignancy in adults. The overall incidence is approximately 5–7 cases per million per year, and climbs to more than 20 cases per million per year by the age of 70 (Egan et al. 1988; Singh and Topham, 2003). It is more common in the Caucasian population, especially those with blue/grey iris. The survival rates at 5, 10 and 15 years are 65%, 50% and 45% respectively (Singh and Topham, 2003). Ninety-two percent of cases of UM arise in the choroid while the remainder arise in the iris (3%) and ciliary body (5%) (Ramasamy et

al., 2014). Choroidal melanomas have the worst prognosis, while iris melanomas have the most favourable. The latter may be due to earlier presentation, as iris melanomas may be detected by the patient externally. Unfortunately, choroidal melanomas are usually detected late, when the patient is symptomatic with decreased visual acuity. This may be due to the involvement of the macula, or when complicated by secondary retinal detachment.

Choroidal Melanoma (CM) is the most common primary malignancy of the eye (Bell and Wilson, 2004). It metastasizes most likely into the liver, followed by pulmonary, bone or even skin metastasis, whereas local spread may occur through the overlying Bruch membrane, into the subretinal space or towards the orbit (Lorigan et al., 1991).

Uveal melanomas account for approximately 98% of all ocular melanomas. More than 90% of intraocular melanomas arise in the choroid, with about 3–4% developing in the iris and the remainder in the ciliary body (Damato and Coupland, 2012a). In Caucasians, uveal melanomas have an incidence of approximately 7 per million per year (Singh et al., 2005). Presentation peaks at the age of sixty years and is rare before adulthood. Males and females are affected in equal numbers, although iris melanomas tend to be slightly more common in women whereas choroidal melanomas are more common in men (Damato and Coupland, 2012a). Risk factors for uveal melanoma include: light skin, blue eyes, tendency to cutaneous naevi, congenital ocular melanocytosis, uveal melanocytoma and neurofibromatosis. The role of sunlight is uncertain but it is noteworthy that most iris melanomas occur inferiorly, where there is less protection from the upper eyelid (Damato and Coupland, 2012b).

Choroidal melanomas initially form a dome-shaped tumour. There is an overlying retinal pigment epitheliopathy, with the multilayering of retinal pigment epithelial cells, lipofuscin accumulation, drusen and retinal pigment epithelial detachment. In Caucasians, most choroidal melanomas are amelanotic or only lightly pigmented and it is the retinal pigment epithelial (RPE) proliferation that gives choroidal melanomas their dark colour. This RPE dysfunction causes retinal degeneration and atrophy, inducing symptoms such as metamorphopsia, blurring, visual field loss and photopsia (Damato and Coupland, 2012b).

Choroidal melanomas are routinely classified as small (<10 mm in diameter and <3 mm in height), medium (10 to 15 mm in diameter and 3 to 5 mm in height), or large (>15 mm in diameter and >5 mm in height) (Zimmerman et al., 1980; Shields et al., 1991). Multiple studies, including the Collaborative Ocular Melanoma Study (COMS, 1998), have specified tumor size as the strongest indicator of metastasis and therefore survival (Mooy and De Jong, 1996). Ten-year survival rates for uveal melanomas have been published as 81.2% for small melanomas, 60.0% for medium melanomas, and 34.8% for large uveal melanomas (McLean et al., 1980). The COMS (1998) additionally identified older patient age as a baseline covariate that affected the prognosis for survival.

Ocular melanomas metastasize hematogenously primarily to the liver but also to lung, bone, kidney, and brain (Zakka et al., 1980; Mooy and De Jong, 1996). Zakka et al. (1980) reported only 75% of ocular melanomas had metastasized at the time of death compared with 96% of nonocular melanomas. Although ocular melanomas are not as aggressive as cutaneous melanomas, they carry a substantial risk of metastasis. In a long-term study of patients treated for uveal melanoma by enucleation in Finland between 1962 and 1981, 61% of patients eventually died as a result of the disease (Kujala et al., 2003). Mortality related to uveal melanoma was 31% by 5 years, 45% by 15 years, 49% by 25 years, and 52% by 35 years. Among patients who died of uveal melanoma, 62%,

90%, 98%, and 100% died within 5, 15, 25, and 35 years, respectively. Once metastasis occurs, survival is less than 7 months (Kath et al., 1993). Therefore, it is important to identify cancerous lesions and begin treatment before metastasis occurs (Bell and Wilson, 2004).

Differential diagnosis of eye tumors is one of the most important problems in ophthalmology. Eye tumors, especially melanoma are very dangerous due to metastasis to other organs. Malignant tumors of the eye makes 0.2 percent of all malignant tumors diagnosed and is every a direct cause of death for every third patient (Paunksnis et al., 2008).

Early detection of these lesions and accurate diagnosis leads to effective assistance. There are several pathologies similar to malignant tumors: choroidal naevus, hemangioma, subretinal hemorrhage, exudative macular degeneration, haemophthalmus. Early diagnosis and tissue characterization is crucial in order to apply the proper treatment, to predict course of disease and to prevent from patient's death (Paunksnis et al., 2008)

Ultrasonic methods stand out in ophthalmology with great informative value among the noninvasive methods. This is one of the main diagnostic methods for establishing the diagnosis of intraocular tumors (Paunksnis et al., 2008).

During the past two decades, improvements in the resolution and reliability of instrumentation and techniques have allowed A-scan and B-scan ultrasonography to join direct visualization, fluorescein angiography, and radioactive phosphorus testing as primary diagnostic modalities in the evaluation of intraocular neoplasms. Because overlying opacities have no effect on the examining ultrasonographic frequencies, ultrasound has the unique ability to depict the nature of intraocular pathology when the media are optically opaque (Goldberg and Hodes, 1977).

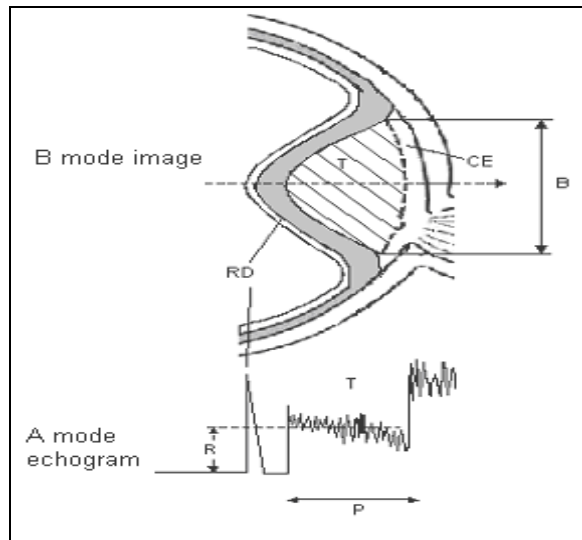
In the last decade, ultrasound probes with higher frequency and higher resolution have been commercialized, such as the 20 MHz probe used for posterior pole studies. Frequency is important in ultrasound because it is directly related to resolution and inversely related to penetration of ultrasonographic images. Moreover, the ultrasonic wavelength is inversely related to the frequency. Thus, the 75  $\mu\text{m}$  of ultrasound at 20 MHz is half the wavelength of a 10MHz transducer and, therefore, is theoretically capable of providing a 2-fold improvement in resolution. This technique may be better for imaging choroidal lesions, such as a UM and SCMT, because it provides a more accurate visual of the episcleral space, resulting in more reproducible lesion height measurements (Coleman et al., 2004).

UH is easier to detect by 20 MHz than by 10 MHz ultrasonography. This ultrasonographic sign appears to be correlated with the height of the tumor. Thus, we believe UH estimation by 20MHz ultrasonography could be used as a significant predictive factor for SCMT growth (Piñeiro-Ces et al., 2014).

Independently, pioneering researchers converged on three important clinical applications of highfrequency B-mode imaging: these were in ophthalmology (Pavlin et al. 1990), dermatology (Hoffmann et al., 1990) and intravascular ultrasound (Nissen et al. 1990). Skin and intravascular applications began in the 20-MHz range, and ophthalmic applications centred in the 40-MHz to 60-MHz range. In each case, unique instrumentation was created to address the specific needs of the applications. The ultrasonic visualisation of living tissue at microscopic resolution is referred to in the literature as “ultrasound backscatter microscopy” or “ultrasound biomicroscopy” (Lizzi and Coleman, 2004).

Ultrasound B-scan image carries information for determination of tumours shape, topography, tumour pervasion into the eye fundus. See **Fig. 1.** (Jurkonis et al., 2012).

Eye tumour size, shape, present of retina detachment, vascular excavation are determined from the B-scan image. Key indicators for intraocular tumor differentiation - geometry of the tumor, size, shape - most commonly used in clinical practice, as well as blood flow, biochemical parameters and additional information is very important. These are the main parameters for clinical decision-making: diagnosis, prognosis and choosing the right tactics for treatment of the patient's (Puzienė et al., 2010).



**Fig. 1.** B – view of the eye tumour (above), A – echogram (below), T – tumour, RD – retinal detachment, CE – choroidal excavation, P – height of tumour, R – mean amplitude of reflected signal, B – base of the tumour.

Simple ultrasonic methods such as A scan and B scan images used in ophthalmology helps to identify intraocular tumors, but does not reflect the microstructure, does not allow them to differentiate (Jurkonis et al., 2012).

To get more information about tumor of the eye and its structure, methods and tools are required to obtain qualitatively new and valuable information (Lizzi et al., 1997b).

Non-invasive ultrasound expert system is designed-consisting of specialized technical equipment – a radio frequency (RF) device to receive and collect RF from the inner eye tumors, and advanced software for data processing and parameterization (Jurkonis et al., 2009).

Application of spectral analysis using non-invasive ultrasound expert system, reliably reflects tissue microstructure, allows to distinguish healthy tissues from the tumor, to identify and differentiate between each other (Lizzi et al., 1997b). RF signal supplies a valuable information of a tissue morphology – shape, homogeneity and structure (Jurkonis et al., 2012).

The main parameters reflecting the structure of tumor is the amplitude envelope of RF signal, spectral slope, spectral intercept and the momentary bandwidth calculated after spectral analysis.

## 1.2 Choroidal melanoma treatment

Various treatment modalities for uveal melanoma have been described in the literature. In recent years, eye-saving procedures have become more widespread, and these include photocoagulation, transpupillary thermotherapy, radiotherapy, local resection, chemotherapy, immunotherapy, and stereotactic radiosurgery (Damato, 2004; Damato and Jones, 2005). Surgical treatment may be associated with postoperative pain, infection, insufficient resection, and secondary eye loss, and it has no superiority over GKS in terms of recurrence (Shields et al., 1991; Damato and Jones, 2005). Chemotherapy and immunotherapy have no curative role; the main objective of treatment in uveal melanoma is to achieve local disease control, and no medical treatment alone can assure this outcome (Damato, 2004).

Of these, photocoagulation and transpupillary thermotherapy are reserved for the management of selected cases with very small tumors (Shields et al., 1996, 1998).

For posterior uveal melanomas, radiotherapy remains the most widely used method of treatment (Shields et al., 1993). Enucleation is indicated for advanced melanomas that occupy most intraocular structures, that have caused severe secondary glaucoma, and that have invaded the optic nerve (Ryan et al., 1989). The principal objective of the treatment is to reduce the risk of death from metastasis and to conserve as much vision as possible while minimizing the risk of enucleation (Toktas et al., 2010).

The goal of all forms of radiation therapy is to destroy the reproductive integrity of a tumour. Ionizing radiation damages the DNA of the malignant cells, which may be misrepaired and also may disrupt the integrity of the chromosome. The effects of this damage become manifest during mitosis, at which point the cells cannot successfully replicate. The timing would depend on the proliferation kinetics of the cellular constituents and it will be longer in tumours with slow turnover, including ocular melanoma. Other consequences of irradiation include changes in growth factors and signal transduction pathways, apoptosis, and the regulation of the cell cycle (Gragoudas, 2006).

Histopathologic studies demonstrated that PBT causes degenerative changes in the tumour (necrosis, fibrosis, balloon cells), decreases the ability of tumour cells to reproduce (fewer mitotic figures), and damages blood supply (Saornil et al., 1992). However, it was shown that post irradiation, most tumours shrink but do not disappear (Boudinet et al., 2007). In 2002, Kaiserman et al. (2002) described echographic changes of tumour thickness and internal reflectivity in uveal melanoma treated by brachytherapy. In our study, we analyze the same dynamics in uveal melanomas treated by PBT (Mosci et al., 2014).

Brachytherapy is a frequently used therapeutic option for the treatment of uveal melanomas. Of the modalities listed here, plaque brachytherapy is the only invasive method utilizing radioactivity that delivers very high dose radiation at the tissue level (Straatsma et al., 1988). Although a high control rate is achieved with plaque brachytherapy, this technique is associated with a high complication rate due to the high doses of radiation the tumor periphery is exposed to (Shields et al., 1990).

Treatment of choroidal melanoma with brachytherapy – suturing a radiation source to the eye – was first reported by Moore in 1930. These early studies by Moore with radon seeds paved the way for the use of other forms of radiation at clinical centers around the world, including cobalt-60 (Brady et al., 1982), ruthenium-106 (Lommatzsch

and Kirsch, 1988), gold-198 (Moura et al., 1985), iodine-125 (Packer et al., 1992) and palladium-103 (Overgaard et al., 1986). Iodine-125 is currently the most commonly used isotope in brachytherapy for choroidal melanoma in the USA, whereas ruthenium-106 and palladium-103 continue to be popular at some centers. Brachytherapy offers an alternative to enucleation in the treatment of choroidal melanoma, allowing globe-salvaging with the possibility of maintaining useful vision (Houston et al.).

Although treatment protocols and selection of tumors for plaque treatment must be individualized and differ among clinical centers, generally acceptable indications for plaque brachytherapy include: (1) selected small choroidal melanomas exhibiting growth or malignant transformation; (2) medium-sized choroidal and ciliary body melanomas in eyes with visual potential; (3) large melanomas with dimensions up to 16 mm in diameter and 8–10 mm in thickness; (4) larger melanomas, especially in monocular patients. However, despite success in sparing enucleation, radiation has profound effects on the surrounding retina and optic nerve, with vision limited by the resulting radiation retinopathy and optic neuropathy (Wen and McCannel, 2009).

The optimal tumoricidal radiation dose for uveal melanoma remains unclear (Trott, 1991), but doses range between 50 and 100 Gy, with doses less than 50 Gy being associated with significant treatment failures (Trott, 1991). Kindy-Degnan et al. (1989) used helium ion radiation and reported on tumor apex dosages ranging between 50 and 80 Gy, showing that regardless of whether 50, 60, 70, or 80 Gy was used, there were no differences in tumor regression, survival, complications, or visual outcomes (Houston et al.).

Brachytherapy is the application of radiation from isotopes over very short distances in contact with a surface. The radiation is distributed over a short distance from a surface or within the target tissue. The isotopes are divided into two broad categories: (1) those that emit  $\gamma$ -rays or X-rays; (2) those that emit  $\beta$ -particles (electrons) (Houston et al.).

Plaque brachytherapy and enucleation were shown to have similar rates of melanoma-specific deaths. In addition, small, large, and juxtapapillary tumors have been successfully treated with plaque brachytherapy. Despite eye preservation, visual morbidity is high secondary to radiation-related complications, including radiation maculopathy and optic neuropathy. Alternative radioisotopes have been investigated to minimize treatment-related effects without significant reductions in visual loss (Houston et al.).

Besides the advantages of being non-invasive and easier for the patient to tolerate, radiosurgery provides a single day treatment that can be completed within a few hours (Fakiris et al., 2013). No other technique offers the same convenience for the patient. Although previous studies have shown GKS to be a minimally invasive, eye-saving treatment modality for uveal melanomas (Fakiris et al., 2013) secondary enucleation is still common with this procedure. Tumor volume and tumor location are thought to be major determinants of intraocular complications after GKS. Egan et al. (1988) proposed that tumors of the ciliary body and tumors larger than 8 mm in height are more likely to require secondary enucleation after treatment (Toktas et al., 2010).

## 2. Objectives of the study

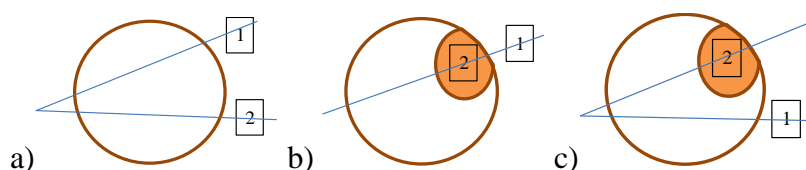
1. Collect ultrasound images and RF signals for comparative evaluation between healthy eye tissues and tissues with intraocular tumors: choroidal melanoma before and after brachytherapy treatment.

2. The aim of this research is to compare parameters of ultrasound signals backscattered from healthy ocular tissues with choroidal melanoma before and after brachytherapy treatment using spectrum analysis of frequency-dependent backscattered radiofrequency (RF).

### 3. Methods and data

The study involved 70 people from 18 to 80 years attending in Hospital of Lithuanian University of Health Sciences Kaunas Eye Clinics consultation diagnostic department with diagnosed intraocular eye tumor – choroidal melanoma before treatment – 35 cases, choroidal melanoma after treatment – 35 cases and 70 cases with healthy eyes.

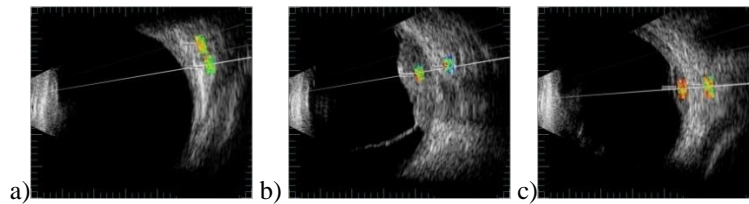
In both eyes of control group, the two ROI (rectangular regions of interest) were selected and used to check if healthy tissues are similar statistically. In the eye with suspicious tissues two manners of ROI selections were done: selecting both ROI at the same direction of B scan vector (b) and selecting each ROI at different B scan vector (c) (See Fig. 2.) Using these two types of tissues imaging could lead to the possibility to check if parameters of backscattered signals from healthy tissues are influenced by acoustic properties of suspicious tissues (Trumpaitis et al., 2014).



**Fig. 2.** ROI selection in B scan images of the eye: a) in eyes of control group; b) in suspicious eyes in one direction; c) in suspicious eyes in two directions. 1 – healthy tissue; 2 – plus tissue.

All subjects underwent a detailed ophthalmic examination. Optical transparent assessment with a slit lamp. Eye fundus was photographed with digital ophthalmoscope Optomed Smartscope M3-1 data was stored in databases.

Ultrasound examination of eye of subjects was performed for evaluation of intraocular tissue structural parameters. The hardware and software system used for acquisition of ultrasound B scan raw signals is described by Jurkonis and others (2009a). Briefly the hardware system could be specified as follow. The ultrasound B scan system is Mentor (Advent, Norwell, MA), with mechanical scanning transducer of 12MHz, this original system is supplemented with signal acquisition system (Jurkonis et al., 2009a, 2009b, 2012). System assures acquisition of raw ultrasound diagnostic signals with 250 MHz sampling frequency and 8 bits amplitude resolution. B scan raw signals were stored into database on computer hard disc and analyzed off-line. Analysis was performed by ophthalmologist using NICDIT v1.2 software. B scan raw signals were loaded into software reviewed and two regions of interest were selected manually. Both regions were of the same length (1.5 mm) in all analyzed cases. Example B scan images with selected regions are presented in Fig. 2.a. Two areas were investigated: healthy tissue area and area with intraocular tumors in the eye of different groups (Trumpaitis et al., 2014).



**Fig. 2.** ROI selection in one direction of B scan images: a) in healthy (control) eye (id221); b) in melanoma eye before treatment (id176); c) in melanoma after brachytherapy treatment (id288).

The raw RF signals from selected regions were analysed in NICDIT v1.2 software algorithms. Radiofrequency row signals were characterized with four parameters: signal envelope amplitude (V), intercept (dB) momentary bandwidth (MHz) and slope (dB/MHz) of approximated backscattered spectra. The amplitude of a radio frequency echo signal distribution equals to the sum of the signals from each reflecting point in the radiation line. Power spectrum of the echo signal is calculated using the discrete Fourier transformation (Trumpaitis et al., 2014).

After analysis the noninvasive ultrasound tissue characterizing parameters were saved into reports. They were compared by applying amplitude and spectral analysis of raw B scan signals. Then parameters matrix was analyzed statistically if there is correlation with intraocular tissue structure. The statistical analysis was performed using the computer program IBM SPSS Statistics. For comparison of differences of quantitative values for two independent groups a Student – normal distribution and the Mann-Whitney test was used. Differences are estimated as statistically significant when  $p < 0.05$  (Trumpaitis et al., 2014).

#### 4. Results of ultrasound tissue characterization

Preliminary conclusions can be made after study of 35 cases with intraocular choroidal melanoma before and 35 cases after brachytherapy treatment, compared with healthy tissue area of 70 cases.

Distribution of patients by sex in 35 cases of melanoma before treatment group was 13 men and 22 women and melanoma after treatment group was 12 men and 23 women

Average age was 65.4 years in melanoma before treatment group and 56.4 in melanoma after treatment group. In control group there were 35 cases with both eyes – 21 men and 14 women, average age was 48.2 years.

In melanoma before treatment group the mean visual acuity (VA) in 27 patients was 0.23, the mean best visual acuity (BCVA) was 0.29, 8 patients had only light perception. In melanoma after treatment group the mean VA was 0.21, BCVA was 0.25, 5 patients had only light perception. In control group the mean VA was 0.67 and BCVA was 0.97.

The mean intraocular pressure (IOP) in melanoma before treatment group was 16.3 mmHg, melanoma after treatment 16.92. In control group – 16.5 mmHg.

Results of B scan showed that the mean basis of melanoma tumor before treatment was 12.8 mm and the mean height was 7.0 mm. In melanoma after treatment tumour – respectively 11.8 mm and 4.9 mm.

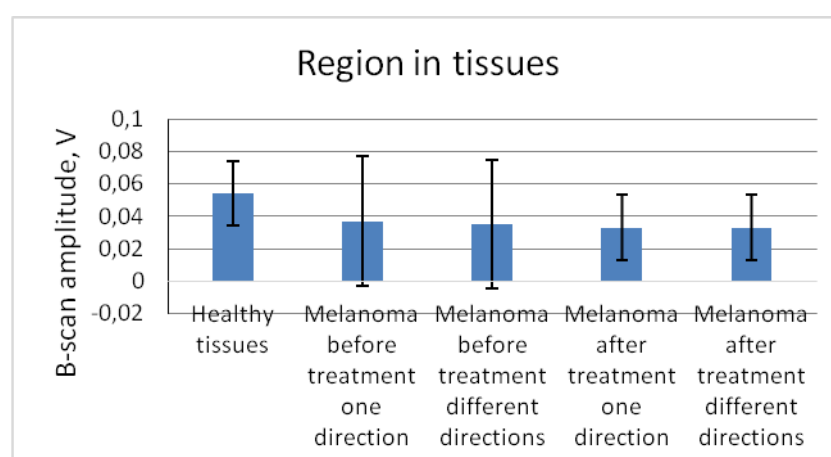


#### 4.1 Amplitude

The comparison of amplitude in exploratory groups revealed that there is no significant difference between the healthy tissue  $0,054 \pm 0,02$  and melanoma tumor before treatment. The statistically significant difference was revealed between the healthy tissue and the melanoma tumor amplitude after treatment in different directions  $0,037$  V ( $p < 0,05$ ).

The comparison of amplitude in plus tissue zone between groups revealed statistical significant difference was between healthy tissues  $0,054$  V and melanomas before treatment  $0,035$ - $0,037 \pm 0,04$  V and melanomas after treatment in both directions  $0,033 \pm 0,02$  V ( $p < 0,05$ ).

The comparison of amplitude in melanomas groups revealed that there is no significant difference between the melanomas before ( $0,035$ - $0,037 \pm 0,04$ ) and after treatment ( $0,033 \pm 0,02$  V) in both directions, although observed amplitude decrease after treatment (See **Fig. 3**.)



**Fig. 3.** Mean B-scan amplitude of tissues in different groups

#### 4.2 Spectral intercept and slope

The comparison of mean spectral intercept between plus healthy zone and exploratory groups revealed the statistically significant difference between healthy tissue  $-11,02 \pm 3,4$  dB and melanoma before treatment group (in one direction  $-21,5 \pm 6,7$  dB and in different directions  $-22,25 \pm 6,7$  dB) and also between melanoma after treatment group (in one direction  $-20,3 \pm 6,03$  dB and different directions  $-20,01 \pm 6,1$  dB) ( $p < 0,05$ ).

No statistically different results were revealed between melanoma group before and after treatment in both directions, although observed spectral intercept increase after treatment. See **Fig. 4**.

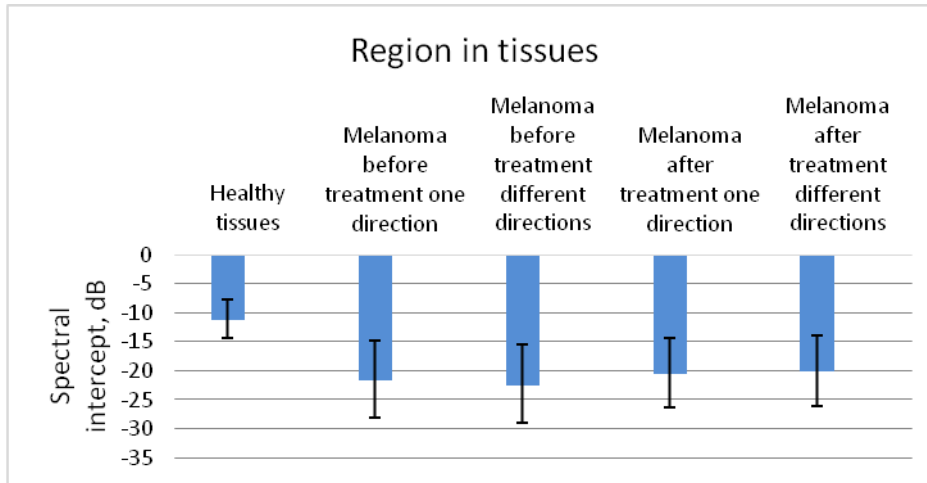


Fig. 4. Mean spectral intercept of tissues in different groups

The comparison of mean spectral slope in plus healthy tissue zone and exploratory groups the statistically significant difference was detected. Comparing healthy tissue –  $1.93 \pm 0,2$  dB/MHz and melanoma before treatment mean spectral slope in one direction –  $1.40 \pm 0,24$  dB/MHz and in different directions –  $1.39 \pm 0,21$  dB/MHz. Also healthy tissues  $1.93 \pm 0,2$  dB/MHz and melanoma after treatment group, mean spectral slope in one direction –  $1.51 \pm 0,2$  dB/MHz and in different directions –  $1.53 \pm 0,23$  dB/MHz ( $p < 0,05$ ).

There significant difference didn't found between the groups of melanoma before treatment mean spectral slope and melanoma after treatment mean spectral slope in both directions, although observed spectral slope decrease after treatment (See Fig. 5.).

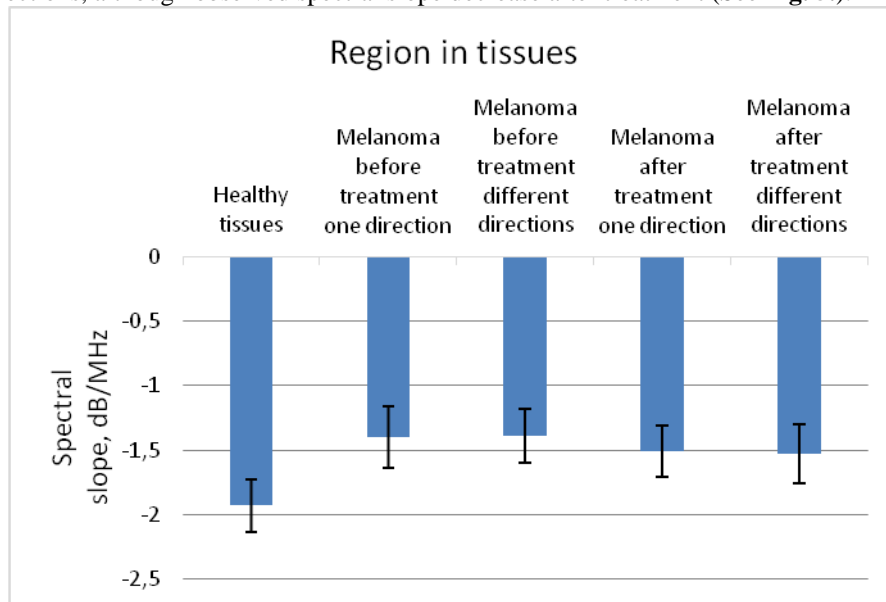
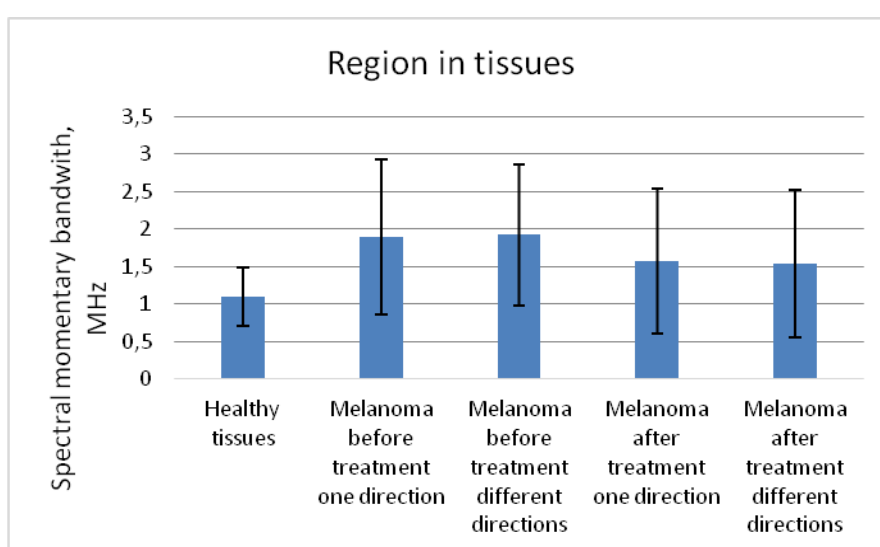


Fig. 5. Mean spectral slope of tissues in different groups

### 4.3 Momentary bandwidth

The results of comparison of mean momentary bandwidth in plus healthy tissues zone and exploratory groups were statistical different: in healthy group  $1,1\pm 0,39$  MHz and melanoma before treatment group in one direction  $1,89\pm 1,03$  MHz and in different directions  $1,92\pm 0,94$  MHz. ( $p<0,05$ ). No statistically different results were revealed between healthy group and melanoma after treatment in one direction  $1,57\pm 0,97$  MHz and in different directions  $1,54\pm 0,98$  MHz.

There was significant difference between groups of melanoma before treatment mean momentary bandwidth in different directions  $1,89\pm 1,03$  MHz and melanoma after treatment mean momentary bandwidth in one direction  $1,57\pm 0,97$  MHz and in different directions  $1,54\pm 0,98$  ( $p<0,05$ ). See **Fig. 6**.



**Fig. 6.** Mean spectral bandwidth of tissues in different groups

The tissues characterising parameters, defined as mean and standard deviation in whole ROIs, extracted from RF ultrasound signals are presented in **Table 1**.

## 5. Discussion

The beginning of using spectrum analysis of frequency-dependent backscattered radiofrequency (RF) data with biological tissues was based on theory (Lizzi et al., 1983). Afterwards this method had been developed by others. (Mamou et al., 2008).

Mamou and Oelze (2013) released a book called "Quantitative Ultrasound in Soft Tissues" in order to describe spectrum analysis of RF diagnostics of soft tissues.

Spectrum analysis of RF data has been used to characterize tissue microstructures in the diagnosis of prostate cancer, ocular tumors, and cardiac abnormalities and to differentiate benign lymph nodes from malignant lymph nodes. It has been shown theoretically that the spectral parameters are related to tissue microstructural properties (e.g., effective acoustic scatterer size and concentration). Ultrasonic spectral analysis

with a high frequency transducer has been used to detect microstructural changes induced by radiotherapy, photodynamic therapy and chemotherapy in tumor xenografts (Lin et al., 2013).

**Table 1.** Differentiation parameters (mean, std. deviation) of B scan ultrasound signals backscattered from intraocular tissues.

Parameters	Region in tissues				
	Healthy tissues	Melanoma before treatment one direction	Melanoma before treatment different directions	Melanoma after treatment one direction	Melanoma after treatment different directions
<b>B scan amplitude, V</b>	0,054±0,02	0,037±0,04	0,035±0,04	0,033±0,02	0,033±0,02
<b>Spectral intercept, dB</b>	-11,02±3,4	-21,5±6,7	-22,25±6,7	-20,3±6,03	-20,01±6,1
<b>Spectral slope, dB/MHz</b>	-1.93±0,2	-1.40±0,24	-1.39±0,21	-1.51±0,2	-1.53±0,23
<b>Spectral momentary bandwidth MHz</b>	1,1±0,39	1,89±1,03	1,92±0,94	1,57±0,97	1,54±0,98

Spectrum analysis techniques were developed to measure reflective tissue properties over a range of frequencies and to quantitatively evaluate subresolution constituents in terms of their effective sizes, concentrations, and acoustic impedances. A striking example of this spectrum analysis technology was a study of malignant melanomas and detection of microarchitectural patterns that recognized lethal patterns with 98% sensitivity. Other applications include tissue layer separation (e.g., choroid and sclera) and the monitoring of subtle changes in tissue microstructure induced by such treatment modalities as radiotherapy and intense therapeutic ultrasound (Lin et al., 2013).

The raw ultrasonic signals backscattered from intraocular tissues were processed and analyzed aiming to characterize healthy and suspicious tissues. The signals from selected regions of the eye tissues are characterized with parameters: B scan envelope amplitude (V), approximated spectral slope (dB/MHz), approximated spectral intercept (dB) and momentary bandwidth (MHz) (Trumpaitis et al., 2014).

Spectral parameters are important for monitoring patients, comparing survival rate while using different therapies. Spectral analysis method was used in clinical trials for investigation of prostate, liver, vascular and breast tissues (Lizzi et al., 1996).

Two-dimensional (2-D) spectrum analysis has been used to detect microstructural changes in eye and prostate cancer tissues (Lizzi, 1997a).

Wachinger et al. (2012) observed that two-dimensional (2-D) spectrum analysis analytic signal leads to a more accurate characterization of structures compared with demodulation.

The equipment that we were using in the present study was described by Sadeghi-Naini (2012). However, Sadeghi-Naini study was limited by the small number of cases (n = 10) and no confirmation of the changes in spectral parameters was obtained from evaluation of the corresponding tissue microstructures.

Mortality rate of melanoma significantly depends on the histological structure (Coleman et al., 1983). Non-invasive ultrasound system which measures spectral analysis parameters (intercept, amplitude and slope) helps to differentiate histological structure of the tumor (Coleman et al., 1983).

Our study has shown that the lower amplitude, lower spectral intercept, high spectral slope and high momentary bandwidth are typical for choroidal melanoma if compared with healthy tissues. This allows us to distinguish healthy tissues from the abnormal tumor tissues and also to identify choroidal melanoma. This study has shown that the lower momentary bandwidth are typical for choroidal melanoma after treatment if compared with melanoma before treatment ( $p < 0,05$ ).

Spectral analysis is useful to assess the efficiency of treatment, but requires a longer observation time.

## 6. Conclusions

The obtained results show that there is statistically significant difference between the RF ultrasound signal parameters (amplitude envelope, spectrum slope, spectrum intercept and momentary bandwidth) in the healthy tissue area and in the area with the intraocular tumor – melanoma before and after treatment ( $p < 0,05$ ).

This study has shown that the lower momentary bandwidth are typical for choroidal melanoma after treatment if compared with melanoma before treatment. It was statistical significant difference ( $p < 0,05$ ).

We also noticed some differences in the RF parameters before melanoma treatment and after treatment but they were not statistically significant ( $p > 0,05$ ): amplitude decrease after treatment, spectral intercept increase after treatment and spectral slope decrease after treatment.

Results of B scan showed that the mean basis and mean height of melanoma tumor after treatment was significantly lower 11,8 mm and 4,9 mm if compared with 12,8 mm and 7,0 mm before treatment.

Non-invasive ultrasound expert system provides the new opportunities in early diagnosis, differentiation of tumors, observation of the process, evaluation of the treatment effectiveness as well as prognosis of survival. Spectral analysis is useful to assess the efficiency of treatment, but requires a longer observation time.

## References

- Aironi, V.D., Chougule, S.R., Singh, J. (2007). Choroidal melanoma: B-scan spectrum. *Indian Journal of Radiology and Imaging*. 17, 8–10.
- Bell, D.J., Wilson, M.W. (2004). Choroidal melanoma: natural history and management options. *Cancer Control: Journal of the Moffitt Cancer Center*. 11(5), 296–303.
- Boudinet, M., Berges, O., LeHuerou, J.Y., Lumbroso-LeRouic, L., Desjardins, L., Laugier, P. (2007). Quantitative echography in the follow-up of patients treated with proton-beam irradiation for primary choroidal melanomas. *Ultrasound in Medicine and Biology*. 33, 1046–1056.
- Brady, L.W., Shields, J.A., Augsburger, J.J., Day, J.L. (1982). Malignant intraocular tumors. *Cancer*. 49, 578–585.

- Castro, J.R., Char, D.H., Petti, P.L., Daftari, I.K., Quivey, J.M., Singh, R.P., Blakely, E.A., Phillips, T.L. (1997). 15 Years experience with helium ionradiotherapy for uveal melanoma. *International Journal of Radiation Oncology Biology Physics*. 39, 989–996.
- Coleman, D.J., Lizzi, F.L., Silverman, R.H., Rondeau, M.J., Smith, M.E., Torpey, J.H. (1983). Acoustic biopsy as a means for characterization of intraocular tumors. American Academy of Ophthalmology, Acta: XXIV International Congress of Ophthalmology, edited by Paul Henkind, MD, J.B. Lippincott Company, Philadelphia, PA, 115–118.
- Coleman, D.J., Silverman, R.H., Chabi, A., Rondeau, M.J., Shung, K.K., Cannata, J., Lincoff, H. (2004) High-resolution ultrasonic imaging of the posterior segment. *Ophthalmology*. 111, 1344–1351.
- Damato, B. (2004). Developments in the management of uveal melanoma. *Clinical and Experimental Ophthalmology*. 32, 639–647.
- Damato, B., Jones, A.G. (2005). Uveal melanoma: resection techniques. *Ophthalmology Clinics of North America*. 18, 119–128.
- Damato, B.E., Coupland, S.E. (2012a). Differences in uveal melanomas between men and women from the British Isles. *Eye (London)*. 26, 292–299.
- Damato, B.E., Coupland S.E. (2012b). Ocular melanoma. *Saudi Journal of Ophthalmology*. 26(2), 137–144.
- Egan, K.M., Seddon, J.M., Glynn, R.J., Gragoudas, E.S., Albert, D.M. (1988). Epidemiologic aspects of uveal melanoma. *Survey of Ophthalmology*. 32, 239–251.
- Fakiris, A.J., Lo, S.S., Henderson, M.A., Witt, T.C., Worth, R.M., Danis, R.P., Des Rosiers, P.M., Timmerman, R.D. (2013). Gamma-knife-based stereotactic radiosurgery for uveal melanoma. *Stereotactic and Functional Neurosurgery*. 85, 106–112.
- Finger, P.T., Berson, A., Ng, T., Szechter A. (2002). Palladium-103 plaque radiotherapy for choroidal melanoma: an 11-year study. *International Journal of Radiation Oncology Biology Physic*. 54, 1438–1445.
- Goldberg, M.F., Hodes, B.L. (1977). Ultrasonographic diagnosis of choroidal malignant melanoma. *Survey of Ophthalmology*. 22, 29–40.
- Gragoudas, E.S. (2006). Proton beam irradiation of uveal melanomas: the first 30 years. The Weisenfeld Lecture. *Investigative Ophthalmology & Visual Science*. 47(11), 4666–4673.
- Hoffmann, K., el Gammal S., Matthes, U., Altmeyer, P. (1989). Digital 20 mhz sonography of the skin in preoperative diagnosis. *Z Hautkr*. 64, 851–858.
- Houston, S.K., Boldt, H. C., Markoe, A.M., Murrayresearch, T.G. Brachytherapy for Choroidal Melanoma. Chapter 145. Section 2. 2275–2289.
- Jurkonis, R., Daukantas, S., Janušauskas, A., Lukoševičius, A., Marozas, V., Jegelevičius, D. (2009a). Synthesis of parametric map from raw ultrasound B-Scan data. *Electronics and Electrical Engineering*. 6(94), 109–112.
- Jurkonis, R., Jegelevičius, D., Marozas, V. (2009b). Virtual Instrument for Ultrasound Signal Sampling and Formation of B scan Image of Eye. Biomedical Engineering Conference “Virtual Instruments in biomedicine 2009“. Klaipėda University, Klaipėda, 15 May, 2009, 55–60.
- Jurkonis, R., Trumpaitis, J., Šarkūnaitė, D., Paunksnis, A. (2012). Application of ultrasound radiofrequency analysis for intraocular tissues differentiation. *Biomedical Engineering Conference 2012*.
- Kaiserman, I., Anteby, I., Chowers, I., Blumenthal, E.Z., Kliers, I., Pe'er, J. (2002). Changes in ultrasound findings in posterior uveal melanoma after Ruthenium 106 brachytherapy. *Ophthalmology*. 109(6), 1137–1141.
- Kath, R., Hayungs, J., Bornfeld, N., Sauerwein, W., Höffken, K., Seeber, S. (1993) Prognosis and treatment of disseminated uveal melanoma. *Cancer*. 72, 2219–2223.
- Kindy-Degnan, N.A., Char, D.H., Castro, J.R., Kroll, S., Stone, R.D., Quivey, J.M., Phillips, T.L., Irvine, A.R. (1989). Effect of various doses of radiation for uveal melanoma on regression, visual acuity, complications, and survival. *American Journal of Ophthalmology*. 107, 114–120.

- Kujala, E., Makitie, T., Kivelä, T. (2003) Very long-term prognosis of patients with malignant uveal melanoma. *Investigative Ophthalmology & Visual Science*. 44, 4651–4659.
- Lin, C., Cao, L., Wang, J., Zheng, W., Chen, Y., Feng, Z., Li, A., Zhou, J. (2013). Ultrasonic spectrum analysis for in vivo characterization of tumor microstructural changes in the evaluation of tumor response to chemotherapy using diagnostic ultrasound. *BMC Cancer*. 13, 302.
- Lizzi, F.L., Greenebaum, M., Feleppa, E.J., Elbaum, M., Coleman, D.J. (1983). Theoretical framework for spectrum analysis in ultrasonic tissue characterization. *The Journal of the Acoustical Society of America*. 73(4), 1366–1373.
- Lizzi, F.L., Astor, M., Liu, T., Deng, C., Coleman, D.J., Silverman, R.H. (1996). Ultrasonic Spectrum Analysis for Tissue Assays and Therapy Evaluation. Cornell University Medical College, 1300 York Avenue, New York, NY, 1002.
- Lizzi, F.L. (1997a). Ultrasonic scatterer-property images of the eye and prostate. In Proceedings of the IEEE Ultrasonics Symposium. Piscataway, NJ, USA.
- Lizzi, F.L., Astor, M., Liu, T., Deng, C., Coleman, D.J., Silverman, R.H. (1997b). Ultrasonic spectrum analysis for tissue assays and therapy evaluation. *International Journal of Imaging Systems and Technology*. 8, 3–10.
- Lizzi, F.L., Coleman, J. (2004). History of Ophthalmic Ultrasound 2004 by the American Institute of Ultrasound in Medicine. *Journal of Ultrasound in Medicine*. 23, 1255–1266.
- Lommatzsch, P.K., Kirsch, I.H. (1988). 106Ru/106Rh plaque radiotherapy for malignant melanomas of the choroid. With follow-up results more than 5 years. *Documenta Ophthalmologica*. 68, 225–238.
- Lorigan, J.G., Wallace, S., Mavligit, G.M. (1991). The prevalence and location of metastases from ocular melanoma: imaging study in 110 patients. *American Journal of Roentgenology*. 157(6), 1279–1281
- Mamou J. and Oelze, M.L. (2013). Quantitative Ultrasound Methods in Soft Tissues. Springer, New York, USA, 3–20.
- Mamou, J., Ketterling, J.A., Silverman, R.H. (2008). Chirp-coded excitation imaging with a high-frequency ultrasound annular array. *Ultrasonics, Ferroelectrics, and Frequency Control, IEEE*. 55(2), 508–513.
- McLean, I.W., Foster, W.D., Zimmerman, L.E., Martin, D.G. (1980). Inferred natural history of uveal melanoma. *Investigative Ophthalmology & Visual Science*. 19, 760–770.
- Modorati, G., Miserocchi, E., Galli, L., Picozzi, P., Rama, P. (2009). Gamma knife radiosurgery for uveal melanoma: 12 years of experience. *British Journal of Ophthalmology*. 93, 40–44.
- Mooy, C.M., De Jong, P.T. (1996). Prognostic parameters in uveal melanoma: a review. *Survey of Ophthalmology*. 41, 215–228.
- Moore, R.F. (1930). Choroidal sarcoma treated by the intraocular insertion of radon seeds. *British Journal of Ophthalmology*. 14, 145–152.
- Mosci, C., Lanza, F.B., Mosci, S., Barla, A. (2014). Quantitative echography in primary uveal melanoma treated by proton beam therapy. *Canadian Journal of Ophthalmology*. 49(1), 60–65.
- Moura, R.A., McPherson, A.R., Easley, J. (1985). Malignant melanoma of the choroid: treatment with episcleral 198Au plaque and xenon-arc photocoagulation. *Annals of Ophthalmology*. 17, 114–125.
- Nissen, S., Grines, C., Gurley, J. Sublett, K., Haynie, D., Diaz, C., Booth, D.C., DeMaria, A.N. (1990). Application of a new phased-array ultrasound imaging catheter in the assessment of vascular dimension: In vivo comparison to cineangiography. *Circulation*. 81, 660–666.
- Overgaard, J., Overgaard, M., Hansen, P.V., von der Maase, H. (1986). Some factors of importance in the radiation treatment of malignant melanoma. *Radiotherapy and Oncology*. 5, 183–192.
- Packer, S., Stoller, S., Lesser, M.L., Mandel, F.S. Finger, P.T. (1992). Long-term results of iodine 125 irradiation of uveal melanoma. *Ophthalmology*. 99, 767–73; discussion 774.
- Pavlin, C.J., Sherar, M.D., Foster, F.S. (1990). Subsurface imaging of the eye by ultrasound biomicroscopy. *Ophthalmology*. 97, 244–250.

- Paunksnis, A., Barzdžiukas, V., Kažys, R., Raišutis, R., Lukoševičius, A., Paunksnis, M., Janušauskas, A., Marozas, V., Jegelevičius, D., Daukantas, S., Kopsala S., Kurapkienė S., Kriaučiūnienė L., Jurkonis R. (2008). A non-invasive expert system for diagnosis of intraocular tumours: the system concept. *Ultragarsas (Ultrasound)*. 63(4), 66–72.
- Puzienė, V., Jegelevičius, D., Lukoševičius, A., Jurkonis, R., Paunksnis, A., Barzdžiukas, V. (2010). Progress towards noninvasive intraocular tumor diagnostics. *Ultragarsas (Ultrasound)*. 65(2), 47–51.
- Piñeiro-Ces, A., Rodríguez Alvarez, M.J., Santiago, M., Bande, M., Pardo, M., Capeáns, C., Blanco, M.J. (2014). Detecting ultrasonographic hollowness in small choroidal melanocytic tumors using 10 MHz and 20 MHz ultrasonography: a comparative study. *Graefe's Archive for Clinical and Experimental Ophthalmology*. 252(12), 2005–2011.
- Ramasamy, P., Murphy C.C., Clynes, M., Horgan, N., Moriarty, P., Tiernan, D., Beatty S., Kennedy, S., Paula, M. (2014). Proteomics in uveal melanoma. *Experimental Eye Research*. 118, 1–12.
- Ryan, S.J., Schachat, A.P., Murphy, R.P. (1989). *Retina*. 1st Edition, Vol. 2. St. Louis: Mosby, p. 170.
- Sadeghi-Naini, A., Falou, O., Hudson, J.M., Kolios, M.C., Czarnota, G.J. (2012). Conventional frequency ultrasonic biomarkers of cancer treatment response in vivo. *Translational oncology*. 6(3), 234–243.
- Saornil, M.A., Egan, K.M., Gragoudas, E.S., Seddon, J.M., Walsh, S.M., Albert, D.M. (1992). Histopathology of proton beam-irradiated vs enucleated uveal melanomas. *Archives of ophthalmology*. 110(8), 1112–1118.
- Shields, C.L., Shields, J.A., Karlsson, U., Menduke, H., Brady, L.W. (1990). Enucleation after plaque radiotherapy for posterior uveal melanoma. *Ophthalmology*. 97, 1665–1970.
- Shields, J.A., Shields, C.L., Donoso, L.A. (1991). Management of posterior uveal melanomas. *Survey of Ophthalmology*. 36, 161–95.
- Shields, J.A., Shields, C.L., De Potter, P., Cu-Unjieng, A., Hernandez C., Brady, L.W. (1993). Plaque radiotherapy for uveal melanoma. *International Ophthalmology Clinics*. 33, 129–35.
- Shields, C.L., Shields, J.A., DePotter, P., Kheterpal, S. (1996). Transpupillary thermotherapy in the management of choroidal melanoma. *Ophthalmology*. 103, 1642–1650.
- Shields, C.L., Shields, J.A., Cater, J., Lois, N., Edelstein, C., Gündüz, K., Mercado, G. (1998). Transpupillary thermotherapy for choroidal melanoma: tumor control and visual results in 100 consecutive cases. *Ophthalmology*. 105, 581–590.
- Singh, A.D., Topham, A., (2003). Survival rates with uveal melanoma in the United States: 1973–1997. *Ophthalmology*. 110, 962–965.
- Singh, A.D., Bergman, L., Seregard, S. (2005). Uveal melanoma: epidemiologic aspects. *Ophthalmology Clinics of North America*. 18(1), 75–84.
- Straatsma, B.R., Fine, S.L., Earle, J.D., Hawkins, B.S., Diener-West, M., McLaughlin, J.A. (1988). Enucleation versus plaque irradiation for choroidal melanoma. *Ophthalmology*. 95, 1000–10004.
- The Collaborative Ocular Melanoma Study (COMS) randomized trial of pre-enucleation radiation of large choroidal melanoma II: initial mortality findings. (1998). COMS report No. 10. *American Journal of Ophthalmology*. 125, 779–796.
- Toktas, Z.O., Bicer, A., Demirci, G., Pazarli, H., Abacioglu, U., Peker, S., Kilic, T. (2010). Gamma knife stereotactic radiosurgery yields good long-term outcomes for low-volume uveal melanomas without intraocular complications. *Journal of Clinical Neuroscience*. 17(4), 441–445.
- Trott, K.R. (1991). The optimal radiation dose per fraction for the treatment of malignant melanomas. *International Journal of Radiation Oncology Biology Physics*. 20, 905–907.
- Trumpaitis, J., Jurkonis, R., Imbrasienė, D., Grizickaitė, A., Paunksnis A. (2014). Application of ultrasound spectral analysis for intraocular tissues differentiation. *Journal of Vibroengineering*. 16(7), 3586.
- Wachinger, C., Klein, T., Navab, N. (2012). The 2D analytic signal for envelope detection and feature extraction on ultrasound images. *Medical Image Analysis*. 16(6), 1073–1084.



- Wen, J.C., McCannel, T.A. (2009). Treatment of radiation retinopathy following plaque brachytherapy for choroidal melanoma. *Current Opinion in Ophthalmology*. 20, 200–204.
- Zakka, K.A., Foos, R.Y., Omphroy, C.A., Straatsma, B.R. (1980). Malignant melanoma: analysis of an autopsy population. *Ophthalmology*. 87, 549–556.
- Zimmerman, L.E., McLean, I.W., Foster, W.D. (1980). Statistical analysis of follow-up data concerning uveal melanomas, and the influence of enucleation. *Ophthalmology*. 87, 557–564.

## Authors' information

**Jurgis Trumpaitis** received M.D. degree in Lithuanian University of Health Sciences Kaunas, Lithuania, in 2006. He finished ophthalmology residency in 2010. Now he works at Hospital of Lithuanian University of Health Sciences Kaunas Clinics as a doctor of ophthalmology. He is a doctoral student at the final year. He is junior researcher in department of Ophthalmology, Neuroscience Institute, Ophthalmology laboratory, Kaunas, Lithuania. His current research interests include analysis of ultrasonic tissue characterization of intraocular tumours.

**Rytis Jurkonis** received PhD degree in Electrical and Electronics Engineering from Kaunas University of Technology, Lithuania, in 2000. Now he works at Biomedical Engineering Institute of Kaunas University of Technology. His current research interests include analysis of raw ultrasonic signals and ultrasonic tissue characterization.

**Ieva Sakalauskaitė** currently is a third year medicine student in Lithuanian University of Health Sciences. She is interested in ophthalmology and ultrasonography.

**Alvydas Paunksnis**, Dr. Habil. Since 1997 Professor at Ophthalmology Clinics of Lithuanian University of Health Sciences, Kaunas. Ophthalmologist since 1970. Chief Researcher of Lithuanian University of Health Sciences Kaunas since 2008. Research interests: imaging, recognition of images in ophthalmology, ultrasonic characterization of eye tissues, e-health, telemedicine.

Received February 11, 2015, revised March 16, 2015, accepted March 19, 2015